This is a digital copy of a book that was preserved for generations on library shelves before it was carefully scanned by Google as part of a project to make the world's books discoverable online.

It has survived long enough for the copyright to expire and the book to enter the public domain. A public domain book is one that was never subject to copyright or whose legal copyright term has expired. Whether a book is in the public domain may vary country to country. Public domain books are our gateways to the past, representing a wealth of history, culture and knowledge that's often difficult to discover.

Marks, notations and other marginalia present in the original volume will appear in this file - a reminder of this book's long journey from the publisher to a library and finally to you.

Usage guidelines

Google is proud to partner with libraries to digitize public domain materials and make them widely accessible. Public domain books belong to the public and we are merely their custodians. Nevertheless, this work is expensive, so in order to keep providing this resource, we have taken steps to prevent abuse by commercial parties, including placing technical restrictions on automated querying.

We also ask that you:

+ *Make non-commercial use of the files* We designed Google Book Search for use by individuals, and we request that you use these files for personal, non-commercial purposes.

+ *Refrain from automated querying* Do not send automated queries of any sort to Google's system: If you are conducting research on machine translation, optical character recognition or other areas where access to a large amount of text is helpful, please contact us. We encourage the use of public domain materials for these purposes and may be able to help.

+ *Maintain attribution* The Google "watermark" you see on each file is essential for informing people about this project and helping them find additional materials through Google Book Search. Please do not remove it.

+ *Keep it legal* Whatever your use, remember that you are responsible for ensuring that what you are doing is legal. Do not assume that just because we believe a book is in the public domain for users in the United States, that the work is also in the public domain for users in other countries. Whether a book is still in copyright varies from country to country, and we can't offer guidance on whether any specific use of any specific book is allowed. Please do not assume that a book's appearance in Google Book Search means it can be used in any manner anywhere in the world. Copyright infringement liability can be quite severe.

About Google Book Search

Google's mission is to organize the world's information and to make it universally accessible and useful. Google Book Search helps readers discover the world's books while helping authors and publishers reach new audiences. You can search through the full text of this book on the web at `http://books.google.com/`

LANE

MEDICAL LIBRARY

LEVI COOPER LANE FUND

LIBRARY
OF
COOPER MEDICAL COLLEGE
DATE Sept 1904
NO. 5686 CLASS 16
~~GIFT OF~~
Purchase

THE

TREATMENT

LANE OF LIBRARY

FRACTURES

BY

W. L. ESTES, A.M., M.D.,

Director, and Physician and Surgeon-in-Chief of St. Lukes Hospital, South Bethlehem, Pa.

PUBLISHED BY THE
INTERNATIONAL JOURNAL OF SURGERY CO.
MEDICAL PUBLISHERS
100 WILLIAM STREET, NEW YORK

LANE LIBRARY

COPYRIGHT, 1900
BY
INTERNATIONAL JOURNAL OF SURGERY

M101
E79
1900

PREFACE.

I shall endeavor, in this series of papers, to discuss the *treatment* of fractures, and only consider the supposed mechanics of the several fractures when it shall be necessary, in order to elucidate or suggest the proper treatment. To replace dislocated fragments of bone and attempt to hold them in place with some dressing or apparatus is not the whole treatment of any condition which is ordinarily called a "fracture." In every case the entire condition will be taken into consideration, as far as an individual experience will permit, and suggestions will be made to meet the several indications usually to be found. While drawing freely upon modern authorities for ideas and suggestions, most stress will be laid upon the measures and methods which a personal experience of fifteen years in a hospital which has furnished a large clientelle of acute surgery, amongst which fractures have been numerous and conspicuous, has proved most valuable and efficient.

* * * * *

I wish to express my grateful appreciation to the surgeons of the Philadelphia Polyclinic, who courteously permitted me to obtain copies of many of their skiagraphs of representative fractures.

THE TREATMENT OF FRACTURES.

FIRST AID AND TRANSPORTATION OF CASES OF FRACTURES.

The essential point in rendering first aid to a person who has suffered a fracture, is to see that no further damage shall be done by the movements of the broken bones. These movements may be produced by the leverage of gravity or by muscular action. Both may be controlled sufficiently for safe transportation, by improvised splints and by very careful handling. The simple fractures of the long bones of the extremities may be immobilized sufficiently by bandaging or tying the extremity firmly to the trunk in case of the upper extremity, or to its fellow in case of the lower extremity. I very strongly deprecate attempts of, or suggestions to laymen to "pull the fracture into place" as soon as they can. As a rule, they should do nothing of the sort. People ought to be taught to fix a broken extremity as nearly in the position in which they find it, as can be done, by quickly applying improvised splints of boards, straw, or sticks, fastened by handkerchiefs, scarfs, or torn linen. The reduction of fractures by laymen at the time of "first aid" is not only an unnecessary cruelty to the injured person, but is apt to be very harmful by disturbing, violently newly lacerated tissues which will be made to bleed far more than they would if left undisturbed, and also to *increase* the laceration of the soft tissues by unskillful attempts at extension and replacements. Unless a fragment is located just beneath the skin and is pressing upon it so severely that there is imminent risk of breaking through the skin, first aid ought never to include reduction of fractured bones except by a *physician*, and then *only* when the physician has

at hand apparatus and splints to retain the set bones so that another setting will not be necessary. Undoubtedly soon after a fracture has occurred, during the general relaxation which accompanies or is one of the phenomena of psychical shock, a fractured bone may easily be reduced by skillful hands and the patient experience very little pain, as this condition is also one of partial or complete anæsthesia. It is very rare, however, for a surgeon to see a fracture as soon after its occurrence as this.

After the extremity has been immobilized the next thing is to have the injured person transported to a place where he may receive a surgeon's care and a permanent setting of his fracture as soon as possible. It requires three persons to carry a patient properly who has a broken lower extremity. Two of them should carry or support the shoulders and hips and the third should carry the injured limb. If a stretcher be used it should be remembered, in cases of fractures of any of the bones of the lower extremity, never to allow the head to be higher than the feet; so if a short and long man carry a stretcher the long man should always be at the foot of the stretcher when the fracture is in the lower extremity. When the fracture is in the cranium the opposite arrangement should prevail. Men carrying an injured person on a stretcher should not keep step, in order to avoid the swinging or oscillating movements produced by this.

Unless the clothing is blood-stained, indicating a wound in connection with the fracture, the clothing should not be removed from the part before transportation. Sleeves and trousers serve as sufficient padding to improvised splints and are useful in this way.

A certain amount of psychical shock precedes or accompanies nearly every fracture, in civil life, which takes place during the waking hours of the injured persons. This, usually, in simple fractures, is not very severe. It is sufficient, however, to make the

patient feel cold and weak, and sometimes nauseated. In transporting and caring for such injuries, warm covers should be applied over the patient (not so bulky over the fractured part as to produce pain by pressure), and, when possible, heat in the form of previously-heated blankets, shawls or hot water bottles. If a physician sees the patient early enough, strychnia would be of service, and sometimes morphia hypodermically, but *no alcohol.* Whiskey or brandy is apt to excite the patient afterwards and render setting the bones more difficult.

When the patient has reached the place for permanent treatment, and has been made warm and as comfortable as possible, the clothing should be removed by *cutting,* not by hauling, or pushing and pulling, as this is very apt to seriously disturb the fracture.

After the surgeon has determined the nature of the fracture, he should provide the splints and bandages necessary to make a permanent retention of the fractured bones after they shall be set, and then and *not until then* proceed to reduce the fracture.

[First aid for compound and complicated fractures will be considered later].

THE SETTING OF A FRACTURE.

A surgeon ought to treat every fracture individually. It is as rare to find any two fractures and displacements exactly alike as it is to find any two extremities exactly alike. As a nearly invariable rule, however, anæsthesia should be employed during the reduction of a simple* fracture if there be no contra-indication in the general condition of the patient and the heart and lungs are healthy. Reduction should not be attempted until proper splints and bandages are at hand for retaining the fragments in place. Except in some special cases, it is rarely necessary to

* It is much easier to reduce and set compound fractures without anæsthesia because of the greater injury to the muscles and greater relaxation and the direct manipulation which is possible.

make a patient go through the double agony of a "*temporary*" and "permanent," or final setting of his broken bones.

In a condition of general anæsthesia and thorough relaxation it is much easier to accomplish restitution of the fragments to the proper position and to obtain good apposition. Besides, in anæsthesia this replacement may usually be accomplished by gentle manipulations and not require the *forceful* extension which, as a rule, without anæsthesia calls out the resistance of all the muscles of the injured member, and under anæsthesia is apt to jam shreds of muscles, torn connective tissue or periosteum between the fragments. One should accomplish the setting by art and not by force, if possible, and it usually is possible. When no comminution has taken place, when the fragments are brought together under anæsthesia, gentle, but firm rubbing of the ends will greatly assist in getting rid of the shreds of soft tissue which almost invariably cling to and get between the fragments, in fractures of the shafts of the long bones of the extremities especially.

If extension is employed (and *some* extension is usually necessary) and there be considerable displacement, it should never be forgotten that at first extension should be made in the *axis of the displacement* and continued until the end of the distal fragment is free from the proximal, and then the extremity may be brought into its proper axis.

After the eyes, careful palpation, and measurements, if necessary, show the deformity is corrected and that good apposition is obtained, some form of permanent fixation and support ought immediately to be put on, while careful retention is maintained by the hands of assistants, or some apparatus. The retaining of the fragments in place until, and during, the application of splints is sometimes very difficult, and frequently requires more skill than the application of the splint itself. The surgeon will do well

frequently to entrust the application of the splint to a less skillful assistant than relinquish the injured member for the "more honorable part." Nowadays a surgeon will rarely be satisfied that a bone of an extremity is properly set until he has verified it by an inspection by means of the X-rays. The fluoroscope and radiographs are great checks on one's self-complacency in the matter of "setting bones," as I have had occasion to know.

SPLINTS.

Modern treatment of fractures inclines greatly towards the simplest possible methods of fixation. Some bold pioneers indeed contend that in some of the simple fractures, if accurate reposition of the fragments can be obtained, no retaining splints are necessary at all. I confess, however, to sufficient conservatism to still believe it is very rarely possible to retain proper apposition (the X-ray shows that accurate apposition after a badly displaced fracture of a long bone is much less often obtained than one formerly supposed) without some form of splint or stiff and supporting dressing.

Plastic splints are surely the best apparatus, when they can be applied; the instances are very few indeed in which this cannot be done. No fixed splints, nor set apparatus can be made to adapt itself to the conditions of every fracture, and great torture is sometimes inflicted in attempting to make them serve when they do not fit. Plastic material, on the other hand, may be made to conform to almost any condition and to fit perfectly without undue pressure or friction. Besides the great comfort afforded the patient, the ease and rapidity of application, the fixidity and unvariableness greatly assist in rapid union, and lessen the chance of "false union," and no bony union at all. In addition to all this the patient is not obliged to be confined to the bed for so long a time; indeed for some fractures of the extremities it is not necessary, with properly applied plastic splints,

for him to remain in bed at all; this preserves his vigor and strength and greatly shortens his business disability.

Ambulant methods of treating fractures are coming much in vogue, and deservedly so. With plaster-of-Paris bandages, some form of stiffening material, and a little ingenuity thoroughly applied, there are no simple fractures of the bones of the extremities, except those of the ossa innominata and upper third of the femur, which require constant confinement to the bed until they are united.

Splints should be applied immediately after setting the bones. In my judgment this ought to be done in a manner to control the fragments and prevent displacement. I am strongly opposed to *temporary* methods of dressing fractures. It is, of course, impossible to place a permanent splint on *every* fracture at once, but in a large majority of cases it can be done. It is not necessary and sometimes very harmful to "wait for swelling to disappear." Swollen tissues are usually benefited by a properly applied bandage, and there is no reason why sufficient pressure should not be made on swollen limbs to retain the fractured ends of bones in place, provided this pressure be from the extremity upwards, and equally distributed. Commonly the swelling rapidly disappears under such a dressing, and the soft tissues are much more rapidly restored to their normal condition. In these swollen conditions the plastic dressings, especially plaster-of-Paris, make ideal splints, as they may be slit and a section cut out and the splint tightened, as soon as the swelling goes down, without disturbing the fractures and with very little discomfort to the patient.

MASSAGE AND PASSIVE MOTIONS AFTER FRACTURES.

There seems to be much diversity of opinion amongst surgeons of the present day as to the time massage should be employed after a fracture of one of

the limbs. Recently it has been advocated as one of the very early procedures in the treatment of fractures. As I am firmly convinced that when good apposition of the fragments has been obtained it should not be endangered by the early removal of the splints, I cannot believe that massage should be employed in the early days of the treatment. The chief argument used in its favor is that it prevents atrophy of the muscles. When a properly fitting plaster-of-Paris splint has been applied to a limb no appreciable atrophy ought to occur during the treatment of an ordinary simple fracture of a long bone. Atrophy occurs from the irregular and too great constriction of some fixed splint or apparatus as a rule, which seriously interferes with the trophic nerves accompanying and distributed to the lymphatic and sub-cutaneous veins and capillaries. If this injurious irregular, or forceful pressure be avoided one rarely sees any atrophy, except some slight loss of subcutaneous fat. The other argument that it promotes union and lessens the mass of ensheathing callus, I very much doubt. The great law of nature which requires functional rest for rapid healing of injuries of any part, (so forcefully annunciated by Hilton, with many illustrations), is nowhere more imperative than in the treatment of fractures. I have never found the frequent change of dressings necessary for the employment of daily massage conducive to rapid union when the bones were well set and the fracture fresh. Besides, the stimulation of the massage results in greater deposition of callus. For this latter reason massage is an exceedingly useful treatment for *delayed* union of bones, and for this purpose I have employed it in several instances with excellent results. I believe the proper time for massage is two or three weeks after fracture in the bones of the upper extremities, and four or five weeks after fracture in those of the lower extremities, *if the bones are slow to unite firmly.* When good apposition has been obtained this expedi-

ent will very rarely be necessary, however. For the rapid restoration of function to the muscles and joints after long confinement, after the fixation splints are removed, or may safely be removed, I have found massage also very useful.

As to passive motion, I think no fixed rule can be given. There is no question that the joints which are in the immediate neighborhood of a fracture will be functionally fixed. As a rule I think this ought te be done by the surgeon's dressing or splints; if it is not done nature usually accomplishes it through the pain motion causes. In either case lack of use will cause some "*stiffness*" in the joint. I have always found this worse when it is done through lack of support by the surgeon. I have never had a permanent anchylosis after a fracture unless a joint was itself seriously injured as well as its bony surfaces, and I have employed passive motions only after union of the fragments has taken place, as a rule. I am not in favor of early passive motions therefore. Besides being unnecessary the motions occasion great pain, and the muscular spasms occasioned by the pain are apt to disarrange the fragments and to interfere with early union, and are apt to provoke too much "reaction" about the fracture and joint and thus defeat the very object of the movements.

SIMPLE FRACTURES OF THE BONES OF THE CRANIUM.

Simple fractures of the bones of the cranium are rare. Out of fifty cases of fractures of the cranium—of all kinds—I have noted but *two* simple and uncomplicated fractures. As a diagnosis of this condition is sometimes very difficult, it is very possible that some injuries set down as "concussion of the brain and cerebritis" may have been simple fractures. These fractures are almost always fissured fractures and occur as the result of indirect violence. They are

found for the most part in the frontal bone and at the base of the cranium—chiefly fractures of the frontal, sphenoid and temporal bones.

The treatment of simple fractures of the cranium consists almost wholly in treating the concomitant conditions of concussion of the brain and sometimes hemorrhage within the cranium. No fixation, nor setting of the bones is necessary, of course, and unless the fissure is very extensive no apparatus or dressing is necessary. In one case of extensive fissure, which occurred at the parieto-occipital junction on the right side, there was so much separation that I thought it necessary to employ firm bandaging for the purpose of holding the bones together. The case was unique besides, in that the separation was apparently *along the lambdoidal suture.* This is the only instance of which I have note or can recall a diastasis or separation at a suture of the cranial bones.

Fissured fractures, in my experience, are found and occur especially at the base of the cranium. In every case of diagnosed fissure of the vault, therefore, one should carefully explore, as far as practicable, and watch anxiously for symptoms of basilar fracture. My observation indicates that these fissures begin as a rule, at the base and extend upwards as a result of indirect violence.*

FRACTURES OF THE BONES OF THE FACE.

Fracture of the Nasal Bones.—In this day of foot ball and boxing contests, the surgeon has not infrequently an opportunity to treat simple fractures of the nasal bones as a variation of the compound fractures which usually result from railroad, factory and mine accidents. These latter are usually complicated also by other severe injuries.

The treatment of simple fractures of the nasal bones,

* The further consideration of this subject will be included in the treatment of complicated fractures of the cranium.

after the hemorrhage has been stopped (the nose usually bleeds freely even if the mucous lining is not broken), consists in elevating and approximating the two bones, which usually are driven backwards and separated from one another. This may sometimes be accomplished by gentle and careful manipulation from the outside, but usually it is also necessary to make some pressure from within the nose. This may be done by the finger of the surgeon if his hands are small. The finger should always be *clean,* and if possible it should be aseptic and lubricated. In case the finger cannot be used, an oval, blunt, smooth instrument may be employed. Great care should be used not to scratch or tear the mucous membrane, as infection is apt to follow. After the bones are restored they may be held in place by plugging the upper and middle straits of the nostrils with iodoform gauze, and by a moulded rubber or cardboard splint on either side of the bridge. It is not well to employ any transverse strips of adhesive plaster to hold this moulded splint, as the pressure is apt again to separate the bones in the median line; fine wire may be used to hold the splint by passing it through and fastening it to either wing of the splint and carrying it back of either ear by a crook, after the manner of the curved ear pieces of a pair of spectacles. In plugging the nasal cavities it is not necessary to fill in the lower canal or strait, so that breathing through the nose is not prevented. I have found the plugging method efficient also in the treatment of fractures of the nasal bones which are accompanied by lacerations of the mucous membrane of the nasal cavities (compound fractures).

A very common complication of fracture of the nasal bones is a detachment of the cartilaginous septum. This is frequently displaced to one or the other side, and unless replaced leaves a very disagreeable spur in the nostrils afterwards; it is also apt to produce slight deformity by causing a deviation of the middle ridge of the nose. Great care must be used in

replacing and holding this cartilage in place. I have found the iodoform gauze packing on either side efficient, as a rule, in accomplishing the desired retention. Fortunately, the vomer rarely is broken as a result of the primary fracture of the nasal bones. Occasionally it happens, however, when very great violence has produced the injury, as after railway accidents. It is almost impracticable to treat a fracture of the vomer—except the inconsequential fracture of the anterior spur which unites with the cartilaginous septum—without some deformity resulting. The fracture of the vomer is usually accompanied by fracture of the nasal bones, nasal processes of the superior maxillary, and fracture of the middle turbinated plate of the ethmoid. Great depression results and it is usually a compound fracture. The treatment requires restoration of the whole bridge of the nose as well as straightening up of the vomer and cartilaginous septum. As these injuries are nearly always compound fractures, it does not specially complicate matters to use some transverse pins, which, as a rule, should be passed through the nasal processes of the superior maxilla about one-half centimetre above and back of the junction of the ala cartilages, *after* the elevation of these processes and the nasal bones has been accomplished. This pin (sometimes two will be required) should pass through the vomer also and be cut off on either side, just near enough to the skin to permit the ends to be well clamped by a perforated shot. After this dressings and apparatus, similar to those used for fracture of the nasal bones, may be used.

These fractures may implicate the body of the ethmoid bone also, in which case a very serious condition of affairs may result. It is then a compound fracture implicating the anterior fossa of the base of the cranium. It is important in these cases, therefore, always to thoroughly disinfect the nostrils, *before* plugging the superior and middle straits; the plugging should extend back to the posterior nares,

and the iodoform gauze used should be thoroughly sterilized. In case of fever and septic symptoms arising, especially if attended with much cerebral irritation, it is very important to establish thorough drainage through the ethmoid canals even at the expense of the olfactory nerves; drain into the nasal cavity and use the utmost care to keep the cavity aseptic, by daily douching and spraying with a warm alkaline antiseptic solution. I have found a solution of bicarbonate and biborate of sodium, oil of eucalyptus, and carbolic acid, a very good one for this purpose. A loop of aseptic silver wire may be used as a drain, passed through the lacerated mucous membrane, and if possible, through the fissured ethmoid bone into the ethmoid cells. After this is done, careful but loose packing of the nares with sterile iodoform gauze, after the manner recommended for fracture of the vomer, should be done, and continued until the cerebral symptoms are gone, and no further watery bloody discharge is perceived, when the silver drain is gently moved. The after-treatment should be the same as that employed for compound fractures of the cranium in other regions.

Fracture of the Malar Bones.—This is a very rare fracture except as a feature of severe crushing of several of the bones of the face, from great violence. I have seen but very few instances of fracture of the malar bones. The last one was accompanied by fracture of the superior maxilla, the ethmoid and the sphenoid bones. The most common seat of fracture is at the maxillary process. Unless badly depressed the treatment will consist in treating the usually accompanying concussion of the brain and nasal hemorrhage. This should be carried out on the lines laid down elsewhere.

When the fragments are depressed the fracture is usually compound. In this case by an incision, if necessary, or through the external wound, elevate the fragments into proper place and *wire* them in posi-

tion. A protective aseptic dressing, after establishing careful drainage, is usually the only further apparatus necessary.

When a compound depressed fracture of the malar bone occurs the body of the superior maxilla on the same side is also frequently broken and depressed into the antrum of Highmore. I think in such a case an incision is demanded and an elevation of the fragments of the maxilla should be performed, wiring if necessary to hold them in place, and a counter opening made through the bone just posterior to the canine fossa into the antrum, and a double loop of silver wire used as a drain; this should pass out through the soft tissues at a point corresponding with the drill hole in the bone. These injuries usually are attended by severe hemorrhage which may require plugging of both the nasal cavities and the outside wound. Careful attempts at asepsis should precede the final dressing and plugging.

Fracture of the Zygomatic Arch.—This fracture is said by Hamilton to occur when the malar bone is broken. Theoretically this ought to be true, but practically it is not the case. In the three or four cases of fracture of the malar bone which I have seen, I have no note of the fracture of the zygoma. The only case I can recall was one which had occured with a fracture in the temporal fossa, the frontal and greater wing of the sphenoid bone being broken. A strong, heavy man fell off a moving train and apparently struck the side of his head and face against a rounded stone. The result was a comminuted fracture of the zygoma and a fissured fracture through the external angular process of the frontal bone, the greater wing of the sphenoid and frontal arch.

Uncomplicated fracture of the zygoma is very rare. Usually no special treatment is necessary, except "soft food," for a week or more, as difficulty in opening the mouth and chewing are prominent symptoms and give great discomfort and uneasiness. When

there is considerable depression and great difficulty in moving the jaw I think an incision down to the bone, elevation of the fragments, and wiring them together ought to be done, under strict aseptic precautions.

Fracture of the Superior Maxilla.—Except fractures of the nasal processes, simple fractures of the superior maxillæ are very rare. I have records of but two cases of uncomplicated fractures of the superior maxillary bone. I have had a number of complicated cases, that is to say cases of compound comminuted fractures and cases complicated by fractures of the malar bones, the inferior maxilla, and other serious injuries.

Next to the nasal processes the most frequent seat of fracture has been the alveolar processes in my experience.

Simple fractures of the superior maxillæ are usually troublesome because of the excessive effusion of blood and the excessive swelling and discoloration which occurs. The bone is exceedingly vascular, and when it is fractured considerable hemorrhage takes place. A moist compress, one saturated with a solution (about 10 per cent.) of chloride of ammonium or sodium, placed over the seat of effusion and held in place by a firm even bandage, will usually be found all that is necessary, together with the recumbent position, and elevated head for two or three days. After this the patient may be up, but should avoid going up and down stairs for a week, if possible, as the jarring produced by the up and down locomotion may dislodge clots and start up hemorrhage afresh, perhaps, in the nostrils or antrum.

Compound fractures of the superior maxilla are not uncommon. The most frequent location of these is the alveolar processes. Hemorrhage is usually very free and in some cases dangerous and difficult to control. The first aid should consist in an attempt to control hemorrhage, as a rule. If the outside of the cheek is involved in the wound, packing of sterile gauze

through the wound into the fracture, and a firm bandage will usually suffice. If the fracture implicates the antrum, the hemorrhage into this cavity may sometimes produce excruciating pain and a sense of impending rupture of the head. In these cases rapid replacement of the fractured bones into good apposition and position and the closure of the lower jaw firmly against the upper, so that the pressure of the molar teeth may retain the fragments, a thick compress externally, and a pressure bandage may suffice to stop the hemorrhage and relieve the excess of the pain. This bandage should remain for five or six hours undisturbed, and then any necessary fixation apparatus may be applied. If the measures suggested above do not relieve the *bursting* pain, pressure upon the common carotid on the affected side may be tried and is sometimes efficient.

In replacing the fragments, careful and gentle manipulation from within the mouth assisted by counter pressure outside will usually restore the displaced bone. As the bone is so exceedingly vascular even badly comminuted fractures unite promptly unless bad infection occurs. It is rarely necessary to remove small fragments unless they are entirely separated or interfere seriously with the restitution of the more important fragments or prevent proper drainage. The rich supply of blood enables these small fragments rapidly to recuperate, and they unite promptly.

As to fixation of the fragments, I have found silver wire passed between the teeth on either side of the fracture, tightly twisted and carefully moulded, or pressed down along the neck of the teeth, so that it rests just along the margin of the gum and fits into the constriction of the teeth, very efficient in retaining fragments when the alveolar process is involved.

In case the palatal process is comminuted as well as the alveolar process, it may be necessary to fashion an apparatus of rubber or celluloid to retain the frag-

ments. I prefer always to fix these inside splints by some arrangement of silver wire or some dental device which shall be wholly within the mouth, rather than by any apparatus which passes out of the mouth and is fixed to some band without.

When the body of the bone is involved in the fracture and there has been hemorrhage into the antrum, and especially if the malar bone has been driven down upon and presses the malar process of the superior maxilla into the antrum, I think it is necessary to open the antrum freely, drain it, and by means of the opening pass up a smooth blunt instrument and press out the depressed bone. Any one who has tried to manipulate a depressed malar bone into place through the mouth knows that he usually fails to accomplish restitution satisfactorily, and always at the expense of badly contused mucous membrane of the inside of the cheeks, and possibly increase of hemorrhage on account of the forceful pressure necessary in this attempt. I think Dr. Hamilton's mention of the recommendation to drain the antrum by drawing a molar tooth and then drilling through the socket, in cases of fracture, is a very harmful one, or may be very harmful. In wrenching out the tooth, fragments of the fractured bone may be torn entirely away from its connections and frightful hemorrhage may result, beside the entire loss of the fragment of bone. I prefer to go into the antrum by lifting up the cheek, incising the soft tissues down to the bone just above the second bicuspid and first molar. Carefully strip back the periosteum for a sufficient distance, drill two holes through the bone a sufficient distance apart into the antrum, and connect the drill holes by snipping out the intervening bone with a small sharp rongeur, or by a sharp chisel operated without blows—simply by pressure of the hand; then pass a pair of sharp pointed scissors through the mucous membrane lining the cavity and tear a sufficient opening, by separating the blades as the scissors are withdrawn. Clots may now

be curetted out and washed out, the cavity explored, and almost any necessary manipulation be performed. Afterwards a drain of iodoform gauze or a tube and iodoform gauze may be introduced, and if necessary prevented from slipping out by attaching it (the gauze or drainage tube), by means of a fine silver wire, to the nearest tooth.

In all fractures of the superior maxilla which are compound, and very few of them are not compound, care should always be employed to thoroughly *drain* the seat of fracture, and the utmost care in disinfection and cleanliness should be practiced during the necessary manipulations or operations for setting the bone and in the after-treatment.

As a rule, the only outside apparatus necessary will be such dressings as may be required by the wounds of the face, and some modification of Barton's bandage for holding the lower jaw closed firmly against the upper.

Fracture of the Inferior Maxilla.—This is a common fracture. It is also compound as a rule. The mucous membrane covering the alveolar process rarely escapes laceration in even so-called simple fractures. The most common seat of fracture I have found to be the body near the mental foramen. Usually the fracture through the rounded lower border is almost transverse, but almost invariably that through the thinner upper border is oblique.

The next most frequent location of fracture, in my experience, is also the body, near the angle, just anterior to the masseter muscle. This is usually an oblique fracture.

I have seen but two cases of fracture of the ramus of the inferior maxilla that I can recall. Unless the soft tissues are very badly lacerated and if the floor of the mouth is not badly implicated, an external wound, which makes the fracture compound, is not a very serious complication. In cases of comminution or multiple fracture it is rather an advantage than

otherwise; for in such cases one does not hesitate to remove small bits of bone which sometimes interfere seriously with good apposition, and to shape the fragments by cutting forceps, so that they may be brought nicely together and properly secured. Besides, when there is an outside wound the ideal treatment of these fractures—wiring the fragments together—may be practiced without any hesitation or compunction.

I do not believe it is always necessary, but I think when there is any serious difficulty in retaining the fragments in place, wiring should be employed without any hesitation. I have never known any evil to result from the operation of wiring the lower jaw, and in many cases it has done me excellent service.

In ordinary fractures at or near the mental foramen it is sometimes difficult on account of the irregular oblique upper border to get good restitution. The outer fragment sags inwards and a little downwards; the muscular spasm is increased by manipulation, and frequently this fragment will not again interlock, as it should, with its fellow. Art, by manipulation, is necessary, not force, and some patience. Once in place it may be controlled while a few strands of silver wire are passed across the gap from the neck of the teeth on either side, twisted and fitted just above the gum, as indicated above in speaking of the treatment of fractures of the superior maxilla. This manner of retaining the fragments in fractures of the maxillæ is a favorite one with me. It must be borne in mind that the two teeth, one on either side next the fracture, are usually loosened by the injury; so the wire should be passed about three teeth away from the fracture on either side if possible. The twisted "knob" of the wire should always be on the outside, between the lips or cheeks and the gum, not inside, as every one has an instinctive propensity for frequently feeling with the tip of the tongue any considerable projection within the mouth which may be

reached by the tongue. The frequent pressure of the tip of the tongue is apt to displace the wire and loosen the grip on the fragments. For this reason, too, the wire should be made to fit as accurately as possible down under the crown of the teeth just above the gum.

The usual splints for fractured lower jaw are of very doubtful value. Commonly all that is necessary in uncomplicated fractures after wiring the teeth is to put on a small mental compress and bandage after the manner of Barton, and so hold the lower against the upper jaw. One practical point ought to be observed and that is, never to bring any pressure on the outer fragment in a *backward direction*, its tendency is to slip that way, so the bandaging must be done very carefully and the mental compress arranged so that only the inner fragment shall feel its pressure.

If a splint seems desirable I prefer usually to make one for the occasion out of felt or thick cardboard, and mould it to fit the indication

Compound comminuted fractures of the lower jaw should be *wired* by drilling one or more holes from in front backwards, through the principal fragments, and by thick silver wire (using as many strands as necessary) coaptating the fragments by twisting the ends of the wire together. These ends may be cut short and the wire left permanently in place, or they may be allowed to come through the external wound and act as a most efficient drain.

The lower jaw is not nearly as vascular as the upper jaw. Small fragments of bone if almost detached should be removed. The function of the bone is excellent afterwards when as much as two-thirds of the vertical thickness has been lost, if the upper border can be preserved.

Even if the teeth are very loose and seem ready to fall out an attempt ought to be made to retain them. Sometimes the assistance of a dentist may be called in to fasten some plate or apparatus to hold them firmly in place.

Perfect drainage should be obtained in treating cases of compound comminuted fracture of the lower jaw. Careful antisepsis should be employed. Asepsis is usually impracticable. An antiseptic alkaline mouth wash should be frequently used during the after-treatment. No chewing should be allowed for at least four weeks, and then only on soft food.

FRACTURES OF THE BONES OF THE TRUNK.

FRACTURE OF THE STERNUM.

Except from gunshot injuries, fractures of the strnum are very rare. I have records of but two cases: The first was a case produced by a crushing blow to the thorax, and was accompanied by fracture of several ribs on both sides and the clavicle on one side. The sternum was fractured transversely near the junction of the manubrium and gladiolus.*

The second case was an incomplete (greenstick?) fracture in the case of a woman about fifty years old, produced by indirect violence. The woman fell forwards down a flight of stairs, made violent efforts to stop her downward progress, and when picked up she was badly bruised about the face and shoulders, but there was no contusion apparent on the chest. It was noticed that a peculiar projection existed in the upper middle part of her chest, which did not lessen as her contusions became better. She was brought to me about fourteen days after the injury. I found a pronounced anterior bowing of the bone at the junction of the manubrium and gladiolus, as I said above. The woman had had considerable respiratory and circulatory disturbance, and considerable local pain and great tenderness. When I saw her her respiration was good and the heart action, while rapid, was rhythmical and clear. She still had pain and tenderness at the seat of fracture. While there was no doubt about the

* This case died in a short time from his multiple injuries.

existence of the fracture (it could not be a simple diastasis because the woman's age was so advanced that ossification must have taken place), I did not think it expedient to risk making it a complete fracture by any forceful attempt at reduction.

The treatment of fractures of the sternum consists chiefly in restricting the motion of the ribs as much as possible during respiration by firmly strapping the chest. Care should be used, as these fractures are usually transverse, not to press upon the end of the lower fragment during the strapping, as this end is apt to be forced backward out of proper apposition with its fellow. In case the patient has the faulty habit of stooping forward in his walk, it may be necessary to employ a plaster-of-Paris jacket or some form of brace with axillary crutches, to prevent the weight of the shoulders from bowing inwards the upper fragment, and thus causing overlapping and possibly persistent oozing of bloody serum into the anterior mediastinum.

During the after-treatment confinement to the house and avoidance of walking should be enjoined for ten days or two weeks. Also dorsal decubitus in bed, as the lateral positions are very apt to displace the fragment when the fracture is complete. Especially important is it to avoid catching cold and to control any existing cough, as the act of coughing may be very harmful and will always be extremely painful.

In some cases produced by great violence, there may be sufficient hemorrhage into the anterior mediastinum to produce severe pressure symptoms on the heart and phrenic nerves. In case respiration and the heart's action are very much disturbed, if perfect rest in bed and strapping do not relieve the symptoms in a few hours, an incision into the thorax and evacuation of the blood, may be done—of course with the strictest possible aseptic precautions. If the incision is made it will be well to so place it that the fragments

may be wired together, as well as the evacuation of the blood be accomplished. The opening in the chest for anatomical reasons would be best done on the left side of the sternum close to its edge, sacrificing the upper border of a costal cartilage, if necessary.

FRACTURES OF THE RIBS.

In this age of large factories with heavy machinery, busy railroads, mines, quarries, and bicycles, fractures of the ribs are quite common. The complicated and compound fractures seem to be most frequent too. In a series of fifty cases analyzed with reference to this point I find that my records show twenty-seven cases of compound complicated fractures. The majority of them were complicated by other serious injuries, and nearly every one was compound by laceration of the pleura and puncture of the lungs.

In my experience, therefore, the majority of the fractures of the ribs are produced by a powerful crushing force applied to a large area of the chest walls, and result from a form of direct violence. Usually one side only is involved, though in a few cases both sides of the chest are crushed.

The simple uncomplicated fractures are usually produced by some form of indirect violence. I have no clear record of a fracture of a rib having been caused by muscular contraction; I cannot doubt, however, that this may occasionally occur.

Usually more than one rib is broken. I have found that those from the fourth to the tenth* are most frequently fractured. The location of the fracture is usually in a line with the axilla, though now and then one finds the break just anterior to the angle, and occasionally a double fracture, one at either location mentioned. I have seen a few instances of diastasis of the costal cartilages from the anterior ends of the ribs, but this form of injury is rare.

*It is not meant that these five ribs are usually all broken in most fractures, but that two or more of them in this region are usually broken.

Treatment of Simple Uncomplicated Fractures of the Ribs.—Simple fractures of the ribs are not serious accidents. They are rarely followed by much displacement of the fragments. The dipping inward of the ends at the seat of fracture, mentioned by some writers, occurs in compound fractures and *very rarely* in simple fractures. So it is not necessary to make any attempt to reduce the fracture.

Rest in bed (which should have a smooth firm mattress) and some simple device for restraining the movements of the chest walls on the affected side is usually all that is necessary. Strapping the chest with strips of adhesive plaster I have found the most efficient method of restraining the movements of the ribs. The straps should be applied only to the affected side, and should extend only a little way beyond the middle line anteriorly and posteriorly. The straps should be of a width which will readily and smoothly adapt itself to the chest. This will vary according to the size and rotundity of the thorax, but an average width is about two inches. Beginning below the diaphragm with one strip, which should be a little broader and longer than the rest, each strip should overlap the preceding, gradually going upwards, until they reach to the upper border of the fourth rib. These strips should be laid on firmly, and *from behind forwards.* Besides these circular strips I would recommend two *vertical* strips laid on under the circular strips, which should extend from the upper lumbar region posteriorly, over the shoulder of the affected side and down to the level of the last rib anteriorly. These strips will add very materially to the restriction of the chest movement.

A common displacement of the ends of the fractured ribs is downward towards the rib below; but I think this displacement is apt to occur and usually does occur, when it happens at all, during the after treatment, or during the reparative process. This may result in a union of the fractured end to the border

of the bone below, and a partial anchylosis (so to speak) of the chest walls may take place. This may be sufficient in extensive fractures to seriously impede the expansion of the lung on the affected side, and of course renders the subject much more liable to the diseases of the lung incident to impaired function and lack of proper expansion. Another, and an important point, is that the jagged, displaced end of the fractured bone lying upon the upper border of its fellow below carries down with it, frequently, the intercostal nerve, which will be continually irritated by the slight movements of the fractured bone (it is quite impossible to prevent this absolutely); this produces severe and sometimes persisting pain, which tortures the patient and frequently causes a localized inflammation of the neighboring pleura and intercostal muscles.

I have never yet had the boldness to cut down upon and restore to the proper position the fragments and wire them together, but I believe if the condition is recognized and cannot be corrected by the flat position in bed, it would be justifiable surgery, in this day of asepticism, to do this operation.

Rest in bed, on a smooth, firm mattress, with no pillows, or with one which is very thin, preserving as long as practicable the dorsal position and not allowing any voluntary turning, and as little use of the extremities as possible, for a week, will usually go far towards preventing the above mentioned displacement.

A circumscribed pleurisy is not uncommon after fracture of the ribs. The sharp pains and the inclination to cough should be controlled by morphia in sufficient doses.

It is necessary, as a rule, to confine the patient to bed for *at least* a week, when more than one rib is broken; for a longer period if there is an inclination of the fractured ends to sink downward. Free and forceful use of the upper extremities should be prohibited for at least three or four weeks after the injury.

Treatment of Compound and Complicated Fractures of the Ribs.—When a man has met with an accident which results in a crush of his thoracic walls, very frequently other serious injuries have occurred. In some cases fractures of the cranium, in others compound fractures of the bones of the extremities. Treatment of these injuries then is usually very complex and various. The injuries themselves are amongst the most serious one meets in a surgical practice. Of twenty-seven cases of complicated fractures of the ribs treated by myself in the last few years eleven died. Besides other serious injuries eight of these fatal cases had lacerations of the lungs. The most common complication was fracture of the cranium. Leaving out of the enumeration the cases having the complications of other almost fatal injuries, the others were compound fractures, that is lacerations of the lung on the affected side. *These* injuries are sufficiently grave, but are, in my experience, not usually attended by fatal results.

Luckily by the time the surgeon sees these cases the ends of the fragments are usually restored to fairly good apposition; no efforts at reduction are necessary, as a rule, then. Occasionally one finds that the ends of the fragments are somewhat turned inward. I am thoroughly convinced of the futility of attempting to correct this by any protracted or forceful manipulation. In the first place, the manipulations are very painful, and cause intense suffering and violent opposition on the part of the patient. With a lacerated, and possibly bleeding, lung absolute quiet and restrained respiration is necessary. One does not, or should not dare to give a general anæsthetic and irritate an already badly injured lung. Any system of pressure by mechanical means is usually not only painful but inefficient in bringing out the ends of the bones. I have found that placing the patient on a firm flat mattress without any pillow and inducing him to lie flat on his back with his lower

limbs extended, is the most efficient manner of restoring the bones to their places. Besides this, strapping the affected side with adhesive strips as indicated before, while the patient is turned upon his "good side," is the only dressing necessary as a rule. These strips should be laid on with the greatest care, so that the bones shall not be pushed in, as the ends of the fragments sometimes have considerable mobility on account of the severe laceration of the intercostal spaces and pleura. If the patient is inclined to be very restless, it is sometimes necessary to confine the arm on the affected side to the side of the chest by a broad binder passed over the arm and around the chest, then pinned snugly so as to hold the arm firmly and not press too hard upon the chest. Full doses of morphia hypodermically should be given. It should be remembered, however, in case the hemorrhage into the bronchial tubes is considerable, that the patient must not be so thoroughly narcotized that he will not be able to empty the lungs occasionally by coughing.

After the patient has been strapped and put properly to bed, the next indication is to meet, as far as possible, the conditions arising from the lacerated lung. There will be, of course, more or less pneumo-hæmo-thorax. If the hemorrhage into the chest cavity is not sufficient to exsanguinate the patient, nor to seriously embarrass the heart's action, this condition will require only indirect treatment. If, however, the hemorrhage seems to be very severe, incision and exsection of the fractured ends of the bones and exploration of the lacerated lung should be done as soon as possible. If the patient's condition is not very low, this operation, with careful asepsis, will add nothing commensurate to his danger, and may result in freeing his chest of blood, and enable one to suture the lung,or stop the hemorrhage with a Pacquelin or galvano-cautery. The anæsthetic which must be given in such cases is *the* serious danger, but this is a lesser evil under the circumstances. This opera-

tion is *very rarely* necessary and will scarcely ever be required except on the left side. The pressure of a large quantity of blood rapidly poured out may very seriously embarrass the heart's action by direct pressure. The atmospheric pressure will usually cause a collapse of the lung when the thorax is opened, but in the cases in which the operation is indicated the lung has already been solidified by the pressure of the blood, so this point is not of so much consequence as it otherwise would be. At the stage of the operation when the thorax is freely opened it is well to turn the patient on his back or even a little towards the affected side, so that the other lung shall have the best possible chance to expand and to perform its task of taking in sufficient air to sustain the patient. Besides, in this position the extravasated blood will run out and be most rapidly evacuated from the chest cavity.

As stated above, in the majority of cases no operation is indicated. The effused blood is usually absorbed, and the lacerated lung heals rapidly unless the lung or thorax have been previously infected by tubercle. In most cases, therefore, the problem is to keep the patient quiet, and as free from suffering as possible, and to relieve as much as possible the embarrassed respiration, and to stop the hemorrhage from the lung. Venesection has been recommended, and is still recommended by some writers, for this condition. I could never persuade myself that this was necessary in any case I have seen. I believe the free use of morphia and the rapid and free administration of *veratrum viride* is of far more value. Bartholow's idea of bleeding a patient into his own capillaries is an excellent one. I have found in veratrum viride a most efficient "dilator of the mesenteric capillaries," a slower of the heart's action, and not an agent so weakening that it harmed the patient. I can heartily recommend this drug for this purpose. I give five drops of Norwood's tincture every hour

until twenty-five drops have been taken, and then continue it in a smaller or larger dose every three hours for twenty-four hours or more.

Convalesence is usually rather slow in these cases. On account of the inclination toward a downward displacement and anchylosis of the ribs at the seat of fracture, the recumbent position upon the flat mattress should be preserved for as long a time as distinct crepitation can be heard by auscultation over the injured locality, and then the upright position should be assumed very gradually, for short intervals only, and tentatively. If sharp pain is experienced, or a cough is set up, the patient should again be put into the recumbent position. After union is complete and firm, the patient should be put upon a course of respiratory gymnastics, in order to improve the lung expansion, to prevent or stretch as much as practicable fibrous adhesions, and to reclaim the normal mobility of the chest walls. A crippled thoracic cavity, bound down lung, and poor expansion, encourage future lung disease, and one should try to prevent this if possible.

FRACTURES OF THE VERTEBRAE.

In civil life fractures of the vertebræ are very rarely compound. Compound fractures of the vertebræ belong especially to military surgery, and are due to direct violence almost invariably. Nowadays, if the case is seen very soon after the injury, compound fractures are simpler injuries, are of less consequence, are easier to treat, and have better prognoses than most of the so-called simple fractures which result from indirect violence. The reason of this is that from direct violence the injury involves a much more limited area, and the integrity of the column and cord are disturbed to a much less degree, as a rule. As compound fractures are so extremely rare in civil practice, the present writing will deal only with simple

and complicated fractures of the spinal column (comminuted fractures of the vertebræ are usually complicated fractures because of the great injury to the neighboring structures, the cord, ligaments and muscles, and will be classed with the complicated fractures). Simple, uncomplicated fractures of the spinal column are due, as a rule, to some form of direct violence also, and they are not as frequent, in my experience, as complicated fractures.

The simple fractures involve usually one of the prominent and more exposed processes, the spinous or transverse processes. They are usually not very grave injuries except in the cervical region. The condition usually called spinal concussion is apt to result as one of the immediate effects, or rather an accompanying or coincident injury. Genuine concussion of the spinal cord, I am convinced, is exceedingly rare. I believe with Herbert Page that the phenomena and symptoms usually attributed to spinal concussion can be much better explained on the hypothesis of spinal hemorrhage, a hæmatomyelia. I think I have seen a few cases of such hemorrhages occurring in or about the spinal cord in such slight degree that they might be properly classed, categorically, concussions, but, except in very neurotic subjects who had previously exhibited marked neuroses, or in cases of rheumatic diathesis, I have never seen any permanent nor persistent sequelæ resulting from these concussions.

Simple Fractures of the Dorsal and Lumbar Regions require only direct manipulation of a very gentle kind, and not prolonged, for the purpose of restoring the fragments to their proper places if the spinous or only one transverse process is involved. It is frequently impracticable to restore the fragments to a good apposition, but in these cases this is not of any great consequence. In fractures of the bodies and pedicles in the dorsal and lumbar regions no attempt should be made to reduce them except an absolutely supine position on a smooth even surface, unless there

be a marked lateral displacement, in which case manual pressure may be used directly over or about the displacement, while very gradual and gentle bending of the column is made by assistants drawing the shoulders and pelvis in a direction opposite to the displacement. This attempt should be made under chloroform anæsthesia, and should be done with the utmost care and gentleness. Except dorsal decubitus on a firm air mattress, I believe no fixation splints or apparatus is necessary after these fractures.

Simple Fractures of the Cervical Vertebræ are always grave injuries. When any marked displacement has taken place these fractures are usually fatal. Unless there be some manifest and direct contraindication either in the nature of the fracture and displacement, or in the condition of the patient, an attempt by gentle manipulations, by traction and direct manual pressure should be made to reduce the fracture. These attempts rarely succeed in bringing about the desired restoration of the fragments and may be harmful. One occasionally succeeds in at least partial reduction, and as the injury must necessarily be fatal if the pressure symptoms are marked, unless they are relieved, the attempt ought to be made, but always with the greatest care and gentleness. Failing to reduce the fracture and the pressure symptoms continuing, I think an operation ought to be done at once. By exposing the seat of fracture, bits of bone, shreds of ligaments, etc., may be removed, and perhaps by direct pressure the fragments which compress the cord may be pushed out of the way or be removed, thus freeing the cord, and, unless the cord has suffered too great injury, life may thus occasionally be saved.

I have seen one case of fracture of the fifth cervical vertebra which I have always regretted was not operated upon at once. I saw the case in consultation ten days after the injury. Myelitis had already set in and the case was hopeless at this time. The man lived six days after I saw him. Though both sensory

and motor paralyses were complete in the four limbs and in the whole trunk, up to the second rib, there were no indications of rapid trophic lesions of the skin (pressure sores), priapism had not been particularly marked nor persistent. I believe the lesion was chiefly from pressure of displaced bone, and had the operation been done promptly, within twenty-four hours after the injury, it might have been possible to save his life. The case was remarkable in that the fracture could be distinctly felt and was unmistakable, the paralysis complete, breathing entirely diaphragmatic, and yet the man lived sixteen days after the injury.

Operations in cases of fracture of the cervical vertebræ must be done very soon after the injury (indeed this is true of the whole vertebral column except below the second lumbar vertebra; the cauda equina bears pressure much better than the cord itself) to be of any service. The fact that very few cases have been saved by operative interference is no legitimate argument against the operation in selected cases, as it is universally recognized that these injuries almost invariably result in death by any other treatment, and there is always a possibility that the operation may save the life (and some degree of usefulness) of the patient.

Fixation of the neck after fracture is absolutely necessary. Spasm of the trapezius and sternocleidomastoid muscles occurs almost as soon as "reaction" takes place, and unless their action is prevented the displacement is apt to be increased and sudden death may occur. There are no proper or special apparatus for these injuries fortunately. (The tendency has been too prevalent to fit fractures of certain bones and regions into certain splints or apparatus, recommended by a surgeon who has had "marvelous success" by means of the dressing, rather than to adapt the dressing to the requirements of each individual case of fracture.) Each case must be fixed and retained according to its special indications and requirements. As a rule, some

form of plastic material is necessary, and some means of continued extension should be employed. Plaster-of-Paris is not at all adapted to the treatment of fractures of the vertebral column in adults, least of all should it be employed in the neck. Thick felt, leather, wood fibre, etc., strengthened by strips of metal after they have been properly moulded, may be employed with advantage. It should never be forgotten that the shoulders must always be fixed also, to make the dressing complete; this is especially necessary if the deltoid muscles are not paralyzed.

I am accustomed to prescribe one of the bromides and ergot immediately after the fracture, in order to try to prevent abnormal congestion about the cord and to prevent restlessness. In case of great pain morphia should be given in sufficient doses to subdue it and assure the quietude of the patient. After three or four days I give bichloride of mercury in medium doses, and continue it for about two weeks or more if the patient bears it well.

Sometimes even after simple fractures there is sufficient hemorrhage to disturb the function of the cord and produce a partial or temporary paralysis. This is the condition usually called concussion of the spine.* The treatment outlined above together with massage of the paralyzed members or parts usually suffices to restore the function, unless a serious complication has resulted in the nature of serious pressure from blood clot or displaced bone, or lacerated nerves or cord, etc. These conditions will be considered under the next head.

A patient should be confined to bed after these fractures until careful manipulation and tentative voluntary movements show that there is no longer any abnormal mobility about the region of the fracture and no pain in gradual or gentle movement of the column. Sitting up should be very gradual and progressive, viz.:

* Concussion of the spine ought to be analogous with the concussions of the brain, which mean lacerations and contusions of the membranes or cord and consequent small hemorrhages. See article on Complicated Fractures of the Cranium.

Begin with short periods and with support, and gradually lengthen the time allowed in sitting up, and modify the support so as to permit increasing function to the column. An average period is six weeks to two months in bed.

An apparatus for relieving the fractured region of weight and restricting its movements should be employed when the patient first begins to get out of bed. This is the time when braces of various kinds are useful and when plaster jackets, etc., may be profitably employed.

COMPLICATED FRACTURES OF THE SPINAL COLUMN.

Under this head may be included (1) Comminuted Fractures, which are always attended with much laceration of the ligaments and muscles, usually considerable hemorrhage, and frequently lacerations of the cord and nerves; (2) Fractures of the bodies and pedicles with marked displacements, which invariably produce pressure upon, and frequently lacerations of the cord; and (3) Fractures of any part of the vertebræ with marked hemorrhage about the cord or within the cord, with consequent paraplegia. The two first classes are usually the result of indirect violence, the third is more commonly produced by direct violence.

Of sixteen fractures of the vertebræ which I have treated in the last few years, twelve were complicated fractures and four might be classed as simple. Of the twelve complicated cases six died, three were cured, and three improved.

Of the simple fractures three were cured and one improved. One was only a fracture of a spinous process, the others were diagnosed as fractures of the transverse processes. Of the three which were cured, one was in the dorsal region (9th and 10th dorsal), and two were in the lumbar region (1st and 2d lumbar). Of those which died, four were in the dorsal and two in the lumbar regions. Of those improved, two were in the lumbar region and one in the dorsal region(6th dorsal).

In all the complicated cases there was complete paraplegia in every case when the patient was received in the hospital.

Complicated fractures, except in the cervical region, require no reduction, at least they are usually not benefited by efforts at reduction. Indeed, even careful manipulation may result in serious additional injury to the cord, on account of the liability to press displaced pieces of bone further upon the cord, and produce laceration, instead of simple pressure.

In the neck, if the displacement can be carefully mapped out by touch, and the fluoroscope, or an X-ray photograph shows that a displaced fragment is pressing upon the cord and there are no sharp edges against the cord, very careful manipulations with extension may be practiced. The friends of the patient should be warned, however, that the effort will be attended with grave danger and that there will be a possibility of a fatal result. These efforts at restitution in the neck if attempted soon after the injury may be done without anæsthesia, as relaxation is generally complete and the patient is paralyzed below the shoulders, and the neighboring nerves are so benumbed that very little pain will result. After the spasm of the sterno-cleido mastoid and trapezins muscles has taken place, anæsthesia (preferably chloroform) should be employed.

More efficient than any other method, I have found an extended position on the back without any pillow, or with but a very thin one, for restoring the continuity of the spinal column. I prefer a smooth, but not absolutely full air mattress for these cases. I have tried water-beds also, but find they permit of much more "sinking in" at the point of fracture; besides, the pressure absolutely unavoidable in changing the bedding and clothing of the patient, and the general nursing functions produce so much motion in the water of the mattress that the patient is very apt to be rolled about by the waves in the mattress.

Fractures of the cervical vertebræ always require some fixation apparatus, as indicated in the section on simple fractures of the cervical spine. Fractures of the dorsal and lumbar regions I believe do best without any apparatus. I have tried various forms of fixation, jackets, splints, etc., etc., but have been most successful without them, and lately have discarded them altogether.

A very important point to establish, if *possible*, and it should be done at once, is what has produced the paralysis, when there is paraplegia. A determination of this will sometimes mean the complete restoration of a patient to usefulness on the one hand, or death or future helplessness on the other. This is because in a very small percentage of cases an operation would relieve pressure and restore the function of the cord, and to do this the operation must be done at once.

In determining the cause of paralysis, a history of the accident will be of great assistance. Moullin thinks that fractures from indirect violence admit of no successful operative interference. The reason of this is that fractures from indirect violence are so extensive and the injury to the cord so severe that the removal of fragments and a general evacuation of the spinal canal will avail nothing. While I think it must be admitted that as a rule this is true, it is not always the case. I have had two cases of fracture of the spinal column with complete paraplegia resulting from indirect violence, which made complete recoveries. The exceptions to the rule are so few, however, that if the fact of indirect violence having caused the fracture can be established, and other signs show indications of a complete disintegration of the cord, an operation will do no good and is contraindicated.

Another important point is the one which Thorburn has very carefully noted and which is absolutely characteristic, namely, when "the site of the lesion relative to the spine is already known, and where

anæsthesia extends as high as this level," the lesion has compressed or destroyed both the cord and the nerve roots. In this case an operation is utterly useless.

Another point which I have noted and found very reliable is, when trophic disturbances begin early, and especially when vaso-motor paralysis is manifest very soon after the injury, an operation will do no good. Vaso-motor paralysis is shown by redness persisting and increasing under slight pressure, as the heels from pressing upon the surface of the bed; the skin on the knees from the pressure of the bed clothing; the end of the great toe from the same cause. This redness comes on in a few hours after the injury, and in twenty-four hours the heels and great toes frequently appear "*bruised,*" and unless the pressure is removed a slough will form in a few hours more.

Thorburn notes another point, viz.: in a complete transverse injury of the cord there is a *lower temperature of the paralyzed part.* He says: "Corresponding with the lower temperatures thus observed is the *frequently noted dryness of the paralyzed limbs,** resulting from a deficient secretion of sweat and giving to the hands a deceptive sensation of warmth."

If all these signs are present with undoubted fracture from indirect violence, an operation will do no good. If, however, these signs are all absent, or many of them not present, it may be possible to relieve the patient by an operation. Having determined that an operation is indicated it ought to be undertaken without delay, to forestall a myelitis or meningitis, the occurrence of either of which will render the result of the operation absolutely negative. On account of the unwillingness of a patient and his friends to have an operation performed soon after a fracture of the twelfth dorsal and first lumbar vertebræ (I finally gained their consent) I operated nine days after the accident. I found the cord intact, but pressed upon by a large clot and a number of bone

*Italics mine.

fragments; the dura mater had only a few slight lacerations, but it was already badly inflamed, as was the cord also. The man died of an ascending myelitis. I believe this man's life could have been saved, and perhaps the use of his limbs restored, by a timely operation.

Laminectomy is not an easy operation, especially when done through lacerated and contused soft tissues and amidst a debris of torn ligaments, displaced bony fragments, etc., etc. It is not in itself a dangerous operation to the patient if careful asepsis is practiced, however.

I have tried the three incisions ordinarily employed through the soft tissues, namely: (1) The V-shaped incision; (2) the H-shaped incision, and (3) the linear incision over the spinous processes. I like the last best. In using this incision the ends of the spinous processes uncovered by the incision should be snipped off by a pair of cutting forceps before closing the incision, in order to prevent them projecting into and interfering with the healing of the superficial tissues. As a rule a chisel should not be used to divide the laminæ; a Hay's or an electric saw, reinforced by a large, sharp cutting forceps, I believe to be better, as the jarring effect of blows in using the chisel may do much harm to an already lacerated cord. As suggested by Bennett (Treve's System of Surgery, p. 252, vol. I.) the operation of laminectomy is sometimes (his very words are: "The symptoms are in no true sense likely to be relieved by the removal of the laminæ *only*, since they are mainly due to backward pressure on the cord from displaced fractured bodies forming the anterior wall of the vertebral canal.") not alone sufficient, since after cleansing the canal of clots, spiculæ of bone, etc., the cord will be found curved over and tightly pressed against the rounded angle of a fractured body of the vertebra. Out of five operations performed for recent fractures I have found the curving bodies of the broken vertebræ to

cause pressure in but one case. In this case it was technically quite easy to perform "Urban's resection of the premedullary angle,"* but the cord was already badly inflamed; the operation was done on the tenth day after the injury; the man died of the myelitis.

If the fracture is below the second lumbar vertebra the immediate necessity for an indicated operation is not so pressing. The nerves of the cauda equina are much tougher than the cord itself is, and will bear pressure longer without serious or irretrievable consequences. Advocates of delayed operation believe, indeed, that laminectomy should be attempted to relieve the effect of a fracture *only* when the injury is below the second lumbar vertebra.

If the case is not one requiring an operation, or if it is decided not to operate, the treatment is very simple, but requires great care and assiduity to accomplish the best results. As I said before, I believe attempts at reduction of the fracture are of very doubful result, and as a rule should not be attempted except as indicated in the foregoing pages. "Concussion" and hemorrhage have identically the same symptoms in the beginning, except that the signs from hemorrhage are later in showing themselves. This differentiation must, as a rule, be determined by the history of the case, however, since the full effect of the hemorhage usually has resulted before the case is seen by the surgeon. Laminectomy I believe to be indicated when there is complete paraplegia from hemorrhage, if there can be established a clear delimitation of the lesion. When paralysis is incomplete and disseminated or irregular from hemorrhage, the case presents the so called concussion symptoms. Thorburn has shown that the hemorrhages of the cord are very commonly central and produce the irregular manifestations.

I am accustomed to treat these conditions at first by bromides and ergot, continued for a week,

*Treve's System of Surgery, Vol. I., p. 252.

then bichloride of mercury is given for more weeks, according to the effect and subsequent manifestations. The patient should be kept on the firm but not absolutely full air mattress, and for a time, *if possible*, confined rigorously to the dorsal position. The greatest care must be exercised in the nursing of these cases. Absolute cleanliness, pads of various shapes and kinds to distribute and relieve pressure, frequent bathing with alcohol, etc., etc., should be practiced and used to prevent bed-sores or to limit them as far as possible. I believe that regular catheterization should be employed, and that the bladder should never be allowed to over distend and empty itself by constant dribbling. It is too often forgotten that the sphincter of the bladder is an *elastic membranous* one and *not* muscular, and that *once* thoroughly forced by the pressure of over distension and constant after-distension, and dribbling allowed to continue, it will most likely mean a permanent condition, even if the patient recovers otherwise. Besides regular catheterization, the bladder should be washed out frequently. After the second week of treatment it is usually necessary to wash out the bladder daily for a time. I think salol given in 0.3 gm. doses three times a day serves a useful purpose in preventing the rapid decomposition of the urine, and in retarding and lessening the almost inevitable cystitis. All the urethral and vesical manipulations, etc., should be conducted with the utmost care as to asepsis and gentleness. A soft catheter as large as the urethra will admit should be used. Massage should be begun during the first week of treatment and be supplemented by passive movements of the paralyzed limbs or portions of limbs, during the second week and thereafter. Faradism may be begun after the first month of treatment and continued daily, or three times a week, alternating with thorough and deep massage during the subsequent treatment. As the flexors usually regain tonicity before the extensor

muscles, one should be careful to prevent distortions of the extremities by preventing too long continued flexion, or mal-position of long continuance. Should bed-sores form, they must be carefully protected and treated antiseptically. The diet should be light and nourishing, chiefly nitrogenous. The bowels must be kept open preferably by enemata—if necessary.

Recovery after complicated fractures is usually very slow. It will be necessary to keep the patient in bed from three months to six months. When the first attempts to sit up are permitted, the column should be thoroughly supported by some well fitting jacket or brace, and the patient should not be allowed to walk or sit for any length of time without this support, until all sense of pain or weakness has entirely departed.

FRACTURES OF THE SCAPULA.

Except fractures of one of the antero-superior processes, fractures of the scapula are rare. Fractures through the body of the scapula below the spinous process are extremely rare in civil life. I have seen but two cases, both of these were due to great violence applied not only to the scapular region but to the whole shoulder. Fractures of the acromion process and of the coracoid process, while not common, are not so very rare; and fractures of the glenoid cavity and anatomical neck are quite common in connection with other crushing injuries of the shoulder. I have never seen, or, at least never recognized, a fracture of the "surgical" neck of the scapula.

Treatment of Fractures of the Body of the Scapula.—This consists chiefly in caring for the accompanying crush of the soft tissues and neighboring bones, as it usually results from great direct violence. Usually there is some little overlapping of the edges of the fragments, but in two cases I saw, a little manipulation with direct pressure upon the bone towards the ribs sufficed to restore the relative positions of the

fragments. I believe with most writers who have treated of these fractures, that accurate coaptation and retention of the fragments in place is almost impracticable; but for good functional results this is not necessary. I found that a thin pad of jute (a thin sack stuffed with jute) placed over the bone and firmly strapped in place with adhesive plaster strips, then an immobilizing dressing consisting of a modified Sayre's dressing, similar to the clavicle dressing, in order to keep the shoulder and upper arm quiet, were sufficient to obtain good union and good functional result. I think the pad directly over the fractured bone and strapping it down upon the ribs served a most useful purpose in spreading apart the fragments which inclined to slide under and over one another, and very materially assisted in the immobilization.

Treatment of Fractures of the Acromion Process.—The outer end of the clavicle is also commonly broken in these fractures, and only when it *is* broken does the fracture require any special apparatus. I have found besides immobilizing the shoulder and upper arm it is usually necessary to raise and support the elbow to prevent the sagging downwards of the shoulder. Some form of dressing similar to a Sayre's dressing for a fractured clavicle I have found most useful. I think a strip of moleskin adhesive plaster, about two inches wide, placed directly over the fractured process, by fixing first an end firmly on the chest midway between the nipple and clavicle and then carrying the plaster firmly across and a *little below* the process and fastening it firmly to the back at the "nape of the neck," is a useful adjunct to the dressing.

Treatment of Fractures of the Coracoid Process.—Bony union after fracture of this process is rarely obtained. The separation is sometimes quite wide between the torn off process and its base, and it is an extremely difficult task to retain the fragments near enough to each other to get good fibrous union. In these fractures the extremely disagreeable position

known as Velpeau's, and his bandage, together with direct pressure by means of adhesive strips or some additional turns of the bandage, forms a useful dressing. It is one of the very few conditions in which I believe this trying form of bandage and position should be employed. In spite of the best efforts of the surgeon pain and functional weakness of the shoulder is apt to persist for many weeks after this fracture. The flexion of the forearm is not particularly disturbed, but the motions of the arm (the elbow) inwards and upwards are much curtailed and usually very painful. This may indicate that the attachment of the coracobrachialis and pectoralis minor are larger and more important at this process than the biceps.

What Dr. Willard Parker called a *trophoneurosis* of the shoulder is very apt to result after injuries which produce a fracture of the coracoid process. This condition is manifested something like a month after the injury. It is one which is quite common after many severe injuries about the shoulder joint. Its characteristic of rapid atrophy of the deltoid muscle, as well as almost constant dull burning pain in the shoulder, which is apt to have frequent exacerbations of exceedingly sharp attacks of pain, has marked it as neuritis of the circumflex nerve. While this is therefore not a distinct sequel of coracoid fracture the frequency of its occurrence should be borne in mind in giving a prognosis after this fracture. This condition is very slow in yielding to treatment. Massage, passive movements, counter-irritation, and a course of electricity by a constant current I have found useful in the order named. Internally I think full doses of one of the iodides (iodide of lithium probably the best) should be given in connection with the local treatment. The treatment requires much time, persistence, and patience on the part both of the surgeon and the patient.

Fracture of the Neck (the Anatomical Neck) and Glenoid Cavity.—The fractures of the anatomical neck

are extremely rare, if they ever occur, in civil practice. They are rarely complete in the sense of being a fracture running completely through this massive process either transversely or obliquely. In some crushing injuries it may be comminuted, and in this way may be considered as completely fractured. Usually the fracture involves more or less of the perimetry of the glenoid cavity, and is oblique. Fractures of the neck and of the glenoid cavity may be regarded for the purpose of treatment as practically the same.

Fractures of the glenoid cavity are sometimes difficult to diagnose, and usually require the process of exclusion to arrive at a diagnosis. The fluoroscope or a skiagraph may settle the question much more quickly and definitely than in former times it was possible to do. On account of the fact that the separation of the fragments is not usually wide, great care must be employed in deciding, even with the aid of the X-rays.

The treatment of these fractures requires little else than a shoulder cap of felt or sole-leather moulded to fit accurately the affected shoulder, careful bandaging and fixation of the arm and elbow. Passive motions gently employed should be begun early in order to prevent adhesion of the head of the humerus. In employing the passive movements, and indeed in putting on an apparatus, care should be exercised not to jam the head of the humerus hard in upon the fractured surface, as this tends to further separate the fragments and to increase the callus and chances of anchylosis in the joint. It is not desirable that the joint be immobilized too long. Two weeks is usually long enough for the shoulder cap and bandage to be worn. Voluntary movements should be encouraged as soon as the fragments have had a chance to adhere, and by this means also prevent disagreeable adhesions in the joint. The pain produced by movements will be an efficient means of preventing too much or too violent movement of the limb.

FRACTURES OF THE CLAVICLE.

"Familiarity breeds contempt." This may in a measure explain why one of the most frequently encountered fractures is usually followed by such poor cosmetic results. While it is rare to find non-union after a fracture of the clavicle, it is very common to find a very unsightly projection of one of the fragments and a large amount of callus as the result of the treatment. Luckily the functional result is not as bad as the union is vicious, when careless or unskillful treatment has resulted in marked deformity after this fracture, and as the fracture occurs very much more frequently in the male sex, and the resulting deformity cannot be appreciated readily, as it is usually covered, suits for malpratice are not common sequelæ of this injury.

It is not my purpose to belittle the difficulties of treating fractures of the clavicle. I readily concede that it is in the adult almost impracticable to obtain good union without some deformity. For this very reason, therefore, I wish to condemn the very common disregard shown by the experienced and seasoned surgeons for this injury, and to urge the necessity of the greatest care and circumspection in treating the fracture.

Fractures of the clavicle illustrate better than almost any other fracture the fact *that perfect immobilization is not necessary in order to obtain firm bony union after fracture.* I am surprised that advocates for the massage treatment of fractures have not used this observation as a very strong argument in favor of their theory of treatment. I doubt that the fragments of a fractured clavicle can be kept even "moderately" quiet by any apparatus which a patient can bear, yet non-union is exceeding rare after these fractures. There is, however, more or less shortening after every fracture of the clavicle (except in the very few transverse fractures when they occur

in children or very weak and poorly developed individuals). This means the fragments overlap, and if they had to stand the vertical strain which would be inevitable in one of the bones of the extremities, this overlapping would prove a source of great weakness and require a long period for functional restitution. Hence, it is not safe to argue too strongly from facts obtained from the results of fractured clavicles with reference to the proper treatment of the fractures of the bones of the extremities.

Simple Fractures of the Clavicle.—The middle part of the clavicle is the section I have most frequently found fractured. I have not found that the "junction of the outer and middle thirds" is more frequently fractured than the section just inside of this point. Next, the external end, and lastly and very infrequently the inner end is fractured.

The fractures are nearly always oblique, unless produced by direct violence, and the deformity is characteristic and uniform, unless the violence has not been sufficient to sever the periosteum under the bone, so that the fibres of the subclavius and the pectoralis major muscles serve to hold the leverage, and the weight of the shoulder, and thus prevent separation of the fragments. The separation usually occurs, however, and the characteristic dropping of the shoulder, projection of the inner fragment and sliding under of the end of the outer fragment is manifest. While this deformity is almost uniform when the bone is broken at or near its middle, the *violence which produces the fracture is decidedly various.* The muscles and nerves of the region are, therefore, very differently affected in the several cases. At one time one muscle is injured, and may be paralyzed from injury to its immediate nervous supply, in another instance this same muscle may be in a state of almost tetanic contraction from irritation of its nerves by a fragment of bone, etc. So that while of a necessity the weight of the shoulder with the

arm, etc., will cause the deformity uniformly, the proper means of restitution and fixation of the fragments must vary somewhat in each individual case. This probably is the reason for the remarkable results obtained by so many various kinds of apparatus, and by no apparatus at all. The only absolutely perfect result I have ever obtained after fracture of the clavicle in a muscular man was without any apparatus at all applied for the retention of the fractured bones. The man had, however, other and serious injuries which obliged him to remain quietly in bed, and his muscles were so badly injured that by putting him flat on his back on a hard mattress, without any pillows and without any apparatus at all, the best result was obtained. I have treated other muscular men in the same manner, but the results were only fairly good. After trying a number of methods I have finally, or at least for the present, settled upon Sayre's adhesive strap method, varying it to meet the indications of each case, as the one which serves in most instances when the fracture is not very near the ends of the bone.

There are a few points in the technique of the Sayre treatment which are worthy of mention. In the first place the adhesive plaster should be the best litharge moleskin plaster and not the rubber adhesive. The latter irritates the skin much more than the former. In putting the first strip on the arm it is well to remember that it is pinned or sewed behind and forms a loop which encloses the arm; it is not necessary, therefore, for it to be made fast by adhesion to the skin. Indeed, this should be avoided, as it interferes with the adjustment of the strap, and is apt to make a wrinkle in the skin of the arm when the strap is drawn tightly across the back. See that this loop does not adhere to the skin of the arm until the strap is adjusted. Another point is: this loop is apt to cut into the skin at its edges and frequently produces considerable irritation of the skin by the direct pressure

of the plaster long continued. This may be obviated by laying under the loop and next to the skin, a layer of thick, white baize or flannel, cut a quarter of an

FIG. 1.

inch wider than the adhesive strip. This may be made to lie smoothly and permanently by making it adhere to the plaster and by pinning it carefully, or better still, by sewing it smoothly in with the plaster, where the end unites with the strip which is to go across the back. This first strip should vary in width, of course, according to the size of the patient, but for a muscular man should be four inches wide, and

should be long enough to reach across the back under the axilla, and across the front of the chest as far as the mammary line of the affected side. In a hairy person the chest should always be shaved over the track the plaster will cover before the adjustment is made.

FIG. 2.

The second strip of plaster should be a trifle narrower than the first and should always be laid on from behind forwards. If the case will admit of it, it is best that it should not go over the olecranon, but be laid on anterior to the point of the elbow, while the hand is in semipronation. In this case the ulna ridge must be carefully protected from pressure by a layer

of absorbent cotton under the plaster where it crosses the forearm. For the sake of leverage in some cases the plaster must be laid over the point of the elbow In these cases the olecranon and external condyle regions must be protected by cutting a hole in the plaster, by absorbent cotton padding, or by nicking the edges of the plaster and carefully fitting it about the bony prominences. I never find it necessary to fasten the hand flat down upon the chest. This position is an exceedingly uncomfortable one, and becomes so irksome to the patient that he is very apt to loosen the straps and bandages in order to partially free his hand and move his fingers. The third strip should be about two and a half inches wide, and be laid on from behind forward over the seat of fracture with a soft compress of absorbent cotton interposed to prevent serious pressure on the skin. In every case the proper position should be obtained by manipulations of the surgeon's hands and by pressure from assistant's hands before the plaster is made fast. It is important not to use the plaster strips to draw the parts into proper position, but to use them simply to hold and retain them in position after they are restored. I always employ a roller bandage as auxiliary to the plaster, thus preventing too much strain on the strips and greatly assisting in the comfort and the retention of the position.

I find it necessary in some cases to assist the first strip of plaster in holding the shoulder backward, by a fourth strip laid on from before backwards, beginning about the groove between the pectoral and deltoid prominences passing backward over the deltoid under the acromion process, and made fast to the back and opposite side of the chest in a slightly oblique and downward direction. This very materially assists in holding the shoulders backwards and lessens the tendency to over-riding on the part of the fragments.

The skin of some patients bears the pressure of

any kind of adhesive plaster so badly that it is impracticable to use Sayre's dressing. In these cases I try by roller bandages laid on in the same directions and sequence as the adhesive strips to retain the injured shoulder in as nearly the Sayre position as possible. Some cases cannot be retained in the proper position by Sayre's dressing. In such cases Dr. Taylor's apparatus or some modification similar to it may do good service.

While I believe the supine position in bed on a flat surface is an excellent one for restoring the fragments to a good position, to lie inanely on his back in bed is so irksome to a patient who has no other serious injury that I would rarely recommend it as a proper treatment for fracture of the clavicle.

Fracture of the Outer End of the Clavicle:—When the fracture occurs to the inner side of the acromio-clavicular ligament, the same treatment applicable to fractures of the middle segments is applicable, as a rule. Fractures outside of the ligament or within its fibres usually result in very little displacement; indeed, a fracture as far towards the middle of the outer third as the middle of the clavicular attachment of the coraco-clavicular ligament may have very little displacement.

These fractures may be treated by very simple bandaging to keep the affected shoulder from sagging forward and immobilizing it as far as practicable. The elbow, as a rule, should be confined as well as the arm, but the forearm may be free in such cases.

Fracture of the Inner End of the Clavicle:—If the fracture occurs within the outer attachment of the sternocleido-mastoid muscle there is drooping of the shoulder, a sliding under of the outer fragment, but the inner fragment is not so much tilted up, indeed scarcely at all if the fracture is near the costo-clavicular ligament. Fractures within the attachment of the sternocleido-mastoid muscles are exceedingly rare, and occur, as a rule, as the result of direct violence.

In these cases the subclavian vessels are very apt to be injured. The fractures of the inner end of the clavicle, which I have seen, have all been very near the sterno-clavicular articulation. Here the fracture is apt to be complicated by a dislocation of the sternal fragment from its union with the sternum. These cases are very difficult to treat successfully. I have found a modified Sayre dressing, with a compress, and as much direct pressure at the seat of injury as the patient and his soft tissues can stand, to be the most efficient treatment.

Naturally, the length of time some sort of apparatus should be worn after fractures of the clavicle must vary in the several cases. I have found, however, that three weeks is an average time that it is necessary to continue the use of the adhesive strips. After this bandaging with a thin flannel bandage, in order to prevent a tendency to further overlapping and to keep the shoulder and arm moderately quiet, is indicated for ten days or two weeks longer. A very gradual and systematic increase of use should be enjoined upon the patient when he is allowed to use the extremity again.

Compound Comminuted Fractures of the Clavicle.—I have not found compound and comminuted fractures of the clavicle which had resulted from *indirect* violence particularly dangerous, unless thay had been infected by careless handling, before I had seen them. Compound fractures are frequently followed by very considerable emphysema of the subcutaneous tissue, but this usually is not a very dangerous complication. The one special danger of compound and comminuted fractures is a possibility of injury to the subclavian vessels. This is rare, however. When it occurs the patient will not require, as a rule, to have his condition treated, as he will be past hope when the surgeon is called to minister. The secondary hemorrhages, which were reported by the older surgeons from ulceration into the vessels, happily do not occur when good antiseptic preparation has been

followed by thorough aseptic after-treatment. The one thing to do when hemorrhage does occur, if the patient is seen in time, is to cut down and tie the bleeding vessel on both sides of the rent in its coats. I do not think the modern suggestion of suturing the tear would be applicable in these cases, as the neighborhood of the fracture and usually greatly injured tissues would render the probability of controlling the hemorrhage very uncertain.

In uncomplicated compound fractures wiring the fragments together is so simple and easy, as a rule, that it is the treatment to be followed in most cases.

Dr. Trowbridge, of Buffalo, has reported an excellent result from the use of a dowel pin. It is a very good suggestion, but the employment of this method would necessitate special preparation, or keeping a suitable pin always in the armamentarium chirurgicum, and except in selected cases this could not be very well done.

Comminuted fractures require, as a rule, careful investigation as to the extent of injuries of the surrounding soft tissues. I think the worst hemorrhage I have ever seen after a fracture of the clavicle occurred in a case of extensive comminution of the bone. It formed an immense hæmatoma which greatly impeded respiration. Pulsation in the third portion of the subclavian was so good that I concluded there was no injury to the artery. An entire absence of venous stasis in the arm and axilla suggested that the vein was also intact, so I treated the fracture on general principles and used gentle compression over the hæmatoma, and the patient made a good recovery.

I would recommend the treatment of comminuted fractures on the same lines as simple fractures of the clavicle, with the caution that compression at the seat of fracture ought to be very gentle and over a larger area than usual, in order to prevent the possibility of driving fragments of bone down upon the vessels or into the thoracic cavity.

As stated in the beginning of this article, it is almost impracticable to obtain a so-called "perfect result" after fracture of the clavicle. There is always some shortening; there is, as a rule, some projection of the fragments and a slight deformity even after very careful treatment of these fractures. If the resulting "bow" is not very marked it rounds off and become much less appreciable in the course of time. Patients and their friends should always be warned at the beginning of the treatment that there will probably be a little deformity left, but that the usefulness of the extremity will not be impaired by the slight overlapping.

FRACTURES OF THE HUMERUS.

The part of the bone most commonly fractured, in my experience with fractures of the humerus, depends to a great extent upon the age of the injured person. Adults seem to have the fractures located most frequently near the surgical neck, and in the shaft of the bone (in the diaphysis), whereas children show a larger percentage of fractures at or near the junction of the epiphyses. Fractures about the condyles are especially common in children.

Intra-capsular Fractures of the Humerus.—The head of the humerus is rarely fractured except by direct violence. In civil practice, therefore, the intra-capsular fractures may be regarded as fractures of the anatomical neck. It is sometimes difficult to make a diagnosis of these fractures without the use of the fluoroscope. In using this instrument in children the epiphyseal cartilaginous union is apt to lead to a wrong conclusion, as it is much more permeable to the X-Ray than the bony tissues. This must be borne in mind in these examinations therefore. Eliminating this source of error, the fluoroscope is an exceedingly valuable aid in diagnosing fractures of the upper end of the humerus. As it is well known

that impaction of the fragments may occur after fractures here, one does not like to employ force or too extended manipulation in order to elicit crepitus. In case of doubt it is safer to treat the injury as one of fracture.

Fig 3. Fracture of the anatomical neck of the humerus (skiagraph)

The fractures of the anatomical neck are usually transverse fractures. When impaction occurs there may be, and indeed usually is, also a longitudinal fracture, a splitting off of the tubercles; so the fracture becomes extra-capsular in these cases.

When the head is broken off transversely at the anatomical neck the expectation of reunion is not very sure; it does take place in *most* of the cases, I have found, however. I have never yet had necrosis of the detached head to occur. I think I have seen a few cases in which there was atrophy or absorption of the head after this fracture.

The treatment of intra-capsular fractures requires, first, careful manipulation to restore the head to its

proper place on the shaft, and then careful placing of the head against the glenoid cavity, so that this counterpressure may hold the fragments together A firm axillary pad is needed to prevent the end of the shaft slipping inwards, a well fitting shoulder cap of leather, or silicate of sodium, (plaster of paris is so friable that unless the cap be made very thick it will crack and crumble, hence it is not so useful as waterglass at this region), or wood fibre, or strong felt should be adapted, and then the whole extremity bandaged from the fingers upwards to prevent œdema of the hand and forearm; the elbow should be supported by a bandage which also confines it to the side a little posterior to the axillary line. I am opposed to early passive movements of the shoulder-joint after these fractures. I think at least four weeks should be allowed before any but the most careful and guarded movement be permitted. On the other hand, frequent passive movements of the elbow, wrist and fingers should be employed and begun early to prevent stiffening of these joints.

The immobilization and bandages should be continued for at least four weeks. Then the shoulder cap may be taken away, and gentle massage and very careful passive movements employed daily, always followed by a fresh bandage, and fixation of the elbow for another two weeks, then a gradual freeing of the elbow, and finally the shoulder may be freed and voluntary movements begun in about eight weeks.

Function is usually restored very slowly after these fractures, especially in middle aged and old people. The capsule is commonly injured and the bicipital groove roughened; the result is that for weeks after the fracture seems united there is an aching pain, worse at night and when a storm approaches; and a trophoneurosis is apt to result on account of the irritation of the circumflex nerve branches. This condition is very discouraging to the patient and requires persistent treatment by massage, galvanism and pas-

sive movements. I have also found that the correction of any possible tendency to lithiasis by a graduated alkaline treatment, is of great service when the patient has previously been subject to rheumatism or gout.

Fractures of the Tubercles of the Humerus.—As separate and uncomplicated injuries, that is, when not a feature of a general comminution of the upper end of the humerus, fractures of the tuberosities of the humerus are very rare. I have seen one case of fracture of the greater tubercle The greater tubercle is the one generally fractured in these rare fractures, and probably muscular contractions cause the injury when not produced by direct violence. The fracture is longitudinal and there is considerable separation, the detached fragment being drawn outwards and upwards by the supra- and infra-spinatus and teres minor muscles. It is very difficult to keep this fragment in place. Relaxation of the muscles by drawing the shoulder backwards should be secured; and then by careful palpation find the small fragment of bone, then push it forward to its place, then hold it in place by a firm compress laid behind and over it and held firmly down by a strip of adhesive plaster laid on from behind forward. A bandage should then be employed to keep the shoulder back and immobilize the shoulder and arm.

The union will probably be fibrous in adults.* The functions of the shoulder-joint are materially lessened; strength and motions are usually impaired for several months. The bandage immobilization should be continued for at least six weeks, then graduated passive movements and massage should be employed. After this a regulated series of active movements in the way at first of "resistance movements," and then light gymnastic exercise will assist in restoring the strength and activity of the injured shoulder.

*These fractures occur in old men chiefly.

Fig. 4. Dr. A. L. Hall's suggestion of treatment of fracture of the greater tuberosity of the humerus, viz., outward rotation of humerus, a small axillary pad and bandage, as indicated in the photograph, to immobilize the shoulder and arm.

Atrophy of the supra-scapular muscles sometimes occurs, as is very well shown by the photograph on page 65. The photograph is one taken of a man sixty-four years of age, a patient of Dr. A. L. Hall, of Fair Haven, N. Y. I am indebted to Dr. Hall for this photograph as well as the other of the same subject showing Dr. Hall's method of outward rotation and fixation of the upper arm in treating the fracture. Dr. Hall's suggestion is a very good one, and was followed in this case by very good functional result. Dr. Hall sums up the result of his treatment in his paper, read before the twenty-eighth annual meeting of the Medical Association of Central New York, Oct. 15, 1895, as follows:

"The result of this case, three months after the receipt of the injury, is briefly stated as follows: fibrous union, as shown by the mobility of the fragment and the presence of crepitus, has taken place. The humerus is not shortened. There is some inward rotation of the arm, in consequence of which the shoulder width is increased three-eighths of an inch. The joint function is impaired, motion being considerably restricted and quite painful. The scapular muscles are wasted, notably so is the infra-spinatus, its extent being shown by the marked depression of the scapular surface in the photograph. The power of active voluntary motion is diminished. Particularly true is this of outward rotation, which is feebly performed. Some improvement of the present condition will unquestionably follow and, upon the whole, the probable result will be better in this instance than is usual with cases occurring at an advanced period of life."

Fractures of the Surgical Neck and Upper End of the Shaft of the Humerus.—For practical purposes the fractures of the surgical neck and fractures of the upper end of the shaft of the humerus may be understood to mean fractures of the upper third of the shaft. These fractures are the most common ones met with in sub-

Fig. 5 Showing atrophy of the supra-scapular muscles after fracture of the greater tubercle of the humerus.

jects past maturity. They are usually oblique. If the fracture is immediately below the tuberosities the difficulty will be in preventing the scapular muscles rotating the upper fragment outward. The lower fragment, though drawn upward and inward for some distance, as a rule occasions very little difficulty after it has been thoroughly reduced. Fractures lower down between the attachments of the latissimus dorsi, the greater pectoral, and the deltoid are difficult sometimes also, on account of rotation and the tilting upward of the fragment. The accompanying photograph No. 6 shows a fracture at this point, and it gave much trouble in the management of the upper fragments on account of the almost tetanic contraction of the external rotators and the pectoral muscles.

In reducing these fractures after extension in the line of deformity, which will be slightly outward, (the elbow abducted) has brought the end of the lower fragment in apposition with the rim of the upper fragment, the elbow should be carried to the side and held within an inch or two of the side of the chest, and the arm rotated outward, so that the hand shall be in a supinated position. While an assistant holds the forearm and elbow in this position, the surgeon should attempt by pressure directly over the upper fragment and by drawing the shoulder backward to bring the upper fragment into accurate apposition with the lower. A strip of adhesive plaster about 7 or 8 c. m. (3 inches) broad, laid on from before backwards, beginning at the groove between the pectoral and deltoid muscles and passing over the head and tuberosities of the bone, then fastened to the back and opposite side, will assist in maintaining this apposition. An axillary pad will be necessary. This ought to be of some aseptic absorbent material, such as sterile absorbent cotton covered with sterile gauze, and should be laid in place after the axillary space shall have been thoroughly bathed with soap and water, and then with alcohol. A moulded

Fig. 6. Fracture of upper end of shaft of humerus.

shoulder cap of leather, wood fibre, or thick felt well padded, should be bandaged firmly in place, the arm immobilized while the extension is kept up at the elbow, and this extension preserved by turns of the bandage from before backwards and downwards across and around the lumbar region. If the elbow is free I have found the patient usually moves it too much ; it should not be supported in the sense of being pushed upwards. I think it is best to immobilize it and keep extension on it as much as necessary. I have not found plaster-of-Paris a good material for splinting fractures of the upper part of the humerus nor about the shoulder-joint. It is apt to crack and crumble and is too cumbersome.

The matter of keeping the elbow near the side while reducing and holding these fractures is of great importance. For this reason it is very difficult to set these fractures properly while the patient is in a recumbent position. He should be sitting, or if he can, standing upright. Anæsthesia in reducing these fractures should not be used, therefore. Happily it is rarely required. In a recent case, the one whose photograph is shown in the illustration, I found so much pressure was necessary to hold the upper fragment down that I employed a segmented Levis' shoulder cap, one which could be placed at various angles, as indicated in the photograph, in this way graduated pressure was employed and controlled the tilting.

Another method I have employed in retaining these fractures is by means of an internal angular splint (see photograph No. 7) made with a rounded upper end and with a hand piece. By a thick pad of absorbent cotton between the splint and the inner surface of the arm and over the rounded upper end of the splint it is made to serve a double purpose, of axillary pad, and by acting as a crutch on the posterior fold (not near the anterior, as the nerves and vessels will not endure the pressure) it serves as a permanent

extensor when fixed, while the arm is drawn down by an assistant. Besides this it fixes the hand in semi-pronation, and keeps up sufficient outward rotation to meet the indications in many cases. With this splint short apposition splints are used over the fracture to help retain the fragment from external and anterior displacement.

The fixed dressing should be continued for four weeks; then passive movements and massage should be gradually and graduatedly employed. A light flannel

Fig. 7. Internal and External angular splints.

or stockinet bandage should be worn for two or three weeks longer, then voluntary movements allowed. In very oblique fractures there is usually some overlapping in spite of careful and skillful treatment, so one must expect a little shortening, the functional result is usually good and prompt, however.

Fractures of the Middle of the Shaft of the Humerus. (See subjoined Skiagraph)—The region most frequently fractured, taking all ages into account, is probably the middle of the shaft of the humerus

By the middle of the shaft I mean the section about 5 c. m. above the intercondyloid groove to the insertion of the deltoid muscle.

Fractures of this portion of the humerus are usually very easily reduced, and very simple apparatus suffices to hold the fragments—unless the fracture is very oblique. In the latter case, care must be exercised to make proper extension (traction) while the applica-

FIG. 8. Fracture of middle of shaft of humerus.

tion of the apparatus is being done. The typical material and method of treating simple fractures of the midshaft is plaster-of-Paris, viz: by a gypsum splint; sometimes it is well to stiffen the plaster during the hardening process by thin apposition splints of wood before and behind.

The one complication which may be feared is injury to the musculo-spiral nerve. In case of persist-

ent wristdrop after a fracture at this point, one should carefully explore the musculo-spiral distribution, and having determined the nerve has been severed, the proper course, I think, would be to cut down upon the nerve at the point of injury and suture it. I would recommend in this case that the fractured bones be also wired together, or, better, united by a plate, which I shall describe later on. The firm union and retention of the ends of the fractured bone by some direct means will prevent a possible severing of the reunited nerve ends. I have recently had two compound comminuted fractures of the shaft which involved the musculo-spiral nerve. I have no recollection nor record of the positive severing of the nerve in a case of simple fracture, but it is a possible complication of this fracture and should be remembered.

About three weeks is usually long enough to retain the splint on the arm for these fractures. The elbow may usually be left free or only temporarily immobilized. There should, therefore, be no great difficulty in restoring the functions of the joints and the extremity. A light bandage, for about a week, and graduated active movement should be begun as soon as the splints are removed.

Fractures of the Lower End of the Humerus.—Fractures of the lower extremity of the humerus may, for all practical purposes, be classed as: (1) Fractures of the lower end of the shaft; (2) Fractures of the condyles; and (3) Supra-condyloid double fractures, so-called T fractures. These are really combinations of 1 and 2 as a rule; very rarely, however, there is a genuine transverse supra-condyloid fracture and a longitudinal fracture of the lower fragment, which implicates the articular surface of the lower end of the humerus—a genuine T fracture. Fractures of the lower end of the humerus occur most frequently in young subjects. Indeed, these fractures are

amongst the most common ones I have had to treat in boys.

In adults fractures at this region are most frequently (in my experience) fractures of the internal condyle, though the other two varieties are seen occasionally.

Fractures of the Lower End of the Shaft of the Humerus.—These fractures are, as a rule, not as oblique as those which occur higher up in the bone; frequently they are almost transverse. The displacement simulates the deformity resulting from an antero-posterior dislocation at the elbow-joint, and this fracture is not infrequently mistaken for this dislocation. Only a few weeks ago a case was sent to me with the diagnosis of "dislocation of the elbow backwards," with the report that two physicians had tried for about an hour, while the patient was anæsthetized, to reduce and retain the dislocated bones without success. Crepitus was very marked in this case, and the fluoroscope showed a supra-condyloid fracture of the humerus

It is not the province of this work to enter into questions of differential diagnosis; but it is of great importance that a correct diagnosis shall be made, or, at least the determination that a simple dislocation and not a fracture exists in a given case. The recollection that antero-posterior dislocations at the elbow-joint are exceedingly rare, and that fractures about the joint are very common, ought to enter very prominently in determining the injury. Crepitus can usually easily be obtained by careful palpation, while abnormal motion is usually much less in the fractures than higher up; yet mobility of the forearm at the elbow-joint can always be obtained, while in dislocations flexion and especially extension is not possible without the exercise of much force. In a case of continued doubt the flouroscope should be used, and this will usually establish the diagnosis. I wish especially to warn those not accustomed to construe skiagraphs, that an X-ray picture of an injured elbow or its im-

mediate vicinity, in a young subject, is very apt to be misleading on account of the cartilaginous junction of the diaphysis and epiphysis, which produces the effect of a solution of continuity in a skiagraph and may thus deceive a sugeon. By the use of the fluoroscope, however, direct ocular inspection together with palpation will demonstrate the relative position of the bony surfaces at once and prevent mistakes.

The displacement of the fragments is usually characteristic. (See Figure.) It is best, as a rule, to employ anæsthesia in reducing this fracture. When the patient is completely relaxed the surgeon should stand on the affected side and a little behind the extremity, and grasp the arm just above the seat of fracture with his right hand, passed between the chest and arm, if it be the left humerus which is fractured (if the right humerus be broken, the left hand should thus be used). Holding firmly, he now directs an assistant, who should already have control of the forearm, to flex the forearm to about a right angle, to pronate the hand (while holding the wrist with one hand, the other should be over the forearm just below the joint), and to make careful extension in the axis of displacement, which is, as a reference to the diagram will show, downward and backwards. The surgeon now places his unengaged hand with his thumb immediately over the upper end of the lower fragment, and as soon as the assistant shall have drawn the forearm downward sufficiently he should push the lower fragments forward, while drawing the upper fragment backward. As soon as the bones are felt to come end to end the assistant continues the extension, but in the normal axis of the arm, downward and a little outward. If the fracture be very oblique the bones will slip out of place unless they are controlled while the retention apparatus is put on. If the fracture be transverse, simple extension, continued as directed above, will suffice to retain the fragments while the splint is placed.

As to the splint itself, I have found plaster-of-Paris reinforced by a short wooden apposition splint placed on the anterior surface of the arm the best apparatus. The apposition splint should be cut so as to fit snugly down into the flexure of the elbow, long enough to reach just above the attachment of the deltoid muscle, and as wide nearly as the anterior surface of the limb. This apposition splint acts as a fulcrum and should be well padded. I think it is important to keep the hand in pronation, and the elbow-joint should

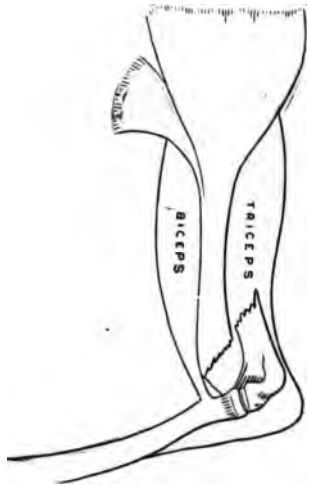

FIG. 9.

be flexed to a right angle. The plaster-of-Paris should reach from the fingers to the axilla. If all goes well, this apparatus should be allowed to remain undisturbed for four weeks; then it should be carefully cut and removed without breaking it. Examine the seat of fracture carefully; if the position is good make careful and gentle passive movements, bathe the limb, or rather sponge it off with alcohol, and replace the splint. After this daily passive movements should be employed, increasing the period and extent every day for two weeks longer. Then the apparatus may be removed and active and passive movements be continued, under direction, for two more weeks.

Usually unrestricted and free voluntary movements may be allowed in eight weeks.

I am decidedly opposed to very early passive movements of the elbow-joint after these fractures. I have never found that anchylosis occurred from a rest of a whole month, and I believe the patients are able to use the extremity freely at a much earlier date when the passive movements are not begun so early. Very early passive movements undoubtedly produce reaction at the seat of fracture; this friction causes enough irritation to stimulate callus formation, which on account of the nearness, is apt to ensheathe the bone as far as the articular surfaces and hinder motions by impinging upon the articular surfaces.

In case the position of the fragments is not as good as desired, when the splint is removed, the patient should be anæsthetized and manual correction be employed. It will be found that this is not very difficult unless the ends of the fragments have been allowed to override one another again. In this case an incision should be made, under careful asepsis, and the bones chiseled apart, the ends freshened and united by wires. Great care must be observed not to injure the musculo-spiral and ulnar nerves in these manipulations.

Fractures of the Condyles of the Humerus.— It seems to me a needles refinement to make a distinction between condylar and epicondylar fractures. This is certainly not necessary in suggesting treatment for fractures of this part of the humerus; to make a distinction between fractures of the condyles which implicate the articular end of the humerus and those which do not, and to call only the former true fractures of the condyles, as Hamilton did, is also unnecessary. The same principles of treatment and the same care and apparatus are indicated in both cases. I shall, therefore, discuss the fractures as condylar fractures, and would suggest

that they be all treated as if they involved the articular ends of the bone.

These fractures are far more common in children, but they are not as rare in adults as Hamilton seemed to think. I certainly have seen a number of cases in adults. They occur as a rule from some direct violence. The internal condyle is most frequently broken, because it is more projecting and is thinner than the outer. As the direct violence which causes the fracture also produces much swelling, it is extremely difficult without the use of the X-rays to make a proper differential diagnosis in many cases.

There is rarely very much displacement. The fractured condyle is usually driven a little upwards, and either backwards or forwards, usually backwards, however.

The forearm should be flexed to nearly a right angle, and under anæsthesia the detached fragment gradually brought into place by careful manipulation. One should not forget the ulnar nerve in reducing the internal condyle fractures. Extreme care should be used not to catch the nerve between the fragments when the patient is anæsthetized and the manipulation is being made. When the fragments are brought quite into place, the forearm should be brought to a right angle with the arm, the elbow covered with a thick layer of absorbent cotton, and a flannel bandage applied from the fingers to the axilla, while an assistant grasps the condyles firmly and holds them firmly against the articular ends of the ulna and radius. Plaster-of-Paris bandages should be put on immediately, unless there is great echymosis or violent contusion of the soft tissues, in which case an angular splint of tin or wood may be used for a few days. I think it is bad treatment to apply evaporating lotions or ice bags to the elbow, and use no fixation apparatus for a number of days. There are always shreds of tissue between the displaced fragments and its base, these together with the extravas-

ated blood in a short time form firm fibrous bands, which clog the bony surfaces and will prevent proper restitution of the fragments. As a rule, too, the swelling yields quickest to firm even compression from the interposed absorbent cotton and an elastic bandage, such as flannel or stockinet. This bandage should always be laid on from the fingers upwards, evenly and smoothly. I think it is also important to put the extremity up with the forearm at a right angle, and the hand in pronation. This gives support to the condyle by the pressure of the articular surfaces and prevents slipping.

The after-treatment of these fractures I think demands perfect rest for at least four weeks. The arguments against early passive movements which were offered in writing of the supra-condylar fractures are even more applicable in condylar fractures. The after-treatment of these two classes of fractures is practically the same and should be conducted upon the same principles.

There is one, or perhaps two complications of condyloid fractures which should receive mention, viz.: (1) Fracture of the head of the radius, and (2) dislocation of the head of the radius. I have seen both of these a number of times in combination with fractures of the condyles. They seem to occur just as often when the inner condyle is broken as when the outer has suffered. Indeed, in the only cases (two) of semi-anchylosis of the elbow-joint I can recall after condylar fractures, the cause seemed to be the detached head of the radius which was displaced upwards and jammed in between the articular surfaces of the joint. It is exceedingly difficult to replace and retain the head of the radius in such fractures by any external manipulations or apparatus. I am coming more and more to the belief that the proper treatment of such complicated fractures is incision and direct replacement of the fragments, and wiring them together. If this cannot be done then removal

of the head of the radius entirely should be practiced.

Dislocation of the head of the radius is not nearly so serious a matter as fracture of the head as a complication of condylar fractures. It is of great importance for the future usefulness of the extremity that the condition be recognized and the dislocation be reduced. It is commoner than fractures of the head, and for this reason, that it may exist and not be recognized, I wish again to emphasize the importance of putting the forearm in pronation and keeping it at a right angle with the arm while the plaster-of-Paris dressing is being applied, and until it hardens.

FIG. 10. Fracture of internal condyle (Skiagraph.)

Supra-Condyloid Double or T Fractures of the Lower End of the Humerus.—The true T fractures are undoubtedly rare. Condylar fractures are sometimes mistaken for these, and I think the reverse is also true. I have had the luck to have seen and treated a number—seven altogether—of what I think

were undoubtedly true T fractures. It is sometimes very difficult to differentiate this fracture from a condylar fracture implicating the articular surface. The fluorscope will usually make clear the condition. Shortening of the distance from the acromion to the point of the olecranon, decided widening of the diameter of the bony surfaces at the lower end of the humerus, crepitus, and unnatural mobility, with great pain and impotence of the affected member, would suggest this fracture. If the swelling has not become very considerable I have found careful palpation under anæsthesia can usually establish the existence of transverse fracture, the split condyles are not difficult to make out after this.

The treatment and apparatus, namely, plaster-of-Paris splint, used for supra-condylar and condylar fractures are applicable also to this fracture. Greater care should be used in replacing the fragments. This replacement should be obtained by extension and manipulations combined, such as were suggested separately for the other two fractures at the lower end of the humerus. Rest, complete and absolute, should be enforced for at least a month, then careful passive movements should be employed daily. After this the same treatment as suggested for the other two kindred fractures.

Dislocation and fracture of the head of the radius may also complicate this fracture, but they are not as apt to occur as with condylar fractures. In the cases I have seen these complications were absent.

Notwithstanding careful treatment anchylosis partial, or well nigh complete, may follow this fracture. I have had the good fortune never to have had but slight and only temporary anchylosis in my cases. I think it is judicious, however, always to warn patients and their friends (as these fractures are most common in boys the parents should be told) that a stiff joint may result. Family practitioners I have found particularly loth to treat fractures near joints.

Fractures about the elbow seem to be especially distasteful to them, because of the very general belief that they will almost surely result in anchylosis. I wish to urge that too early and injudicious movements of the elbow furnish one cause for anchylosis, and another and very important one is the unrecognized complication of fracture or dislocation of the head of the radius. I believe absolute rest and careful replacement of the radius will obviate to a very great extent the danger of anchylosis, and I would warn practitioners to regard most carefully these two points in treating fractures at the lower end of the humerus.

FRACTURES OF THE BONES OF THE FOREARM.

FRACTURES OF THE ULNA.

Fractures of the Olecranon Process. While I think it is true that most of the fractures of the olecranon are produced by direct violence, it is also true that muscular action will also, and does occasionally, produce these fractures.

When produced by violent contraction of the triceps muscle the fracture occurs near the tip of the process; fractures of the middle are occasioned by direct violence, and this is the commonest variety. Fractures through the base are rare. On account of the great comparative strength and thickness of the bone at the base of the olecranon the fractures at this point are oblique, not transverse as they are at the other points.

Usually the swelling is so great very soon after the ordinary fractures that immediate restitution of the fragment, which in these fractures is nearly always drawn up by the triceps muscle, is very difficult. In a recent case I was very much tempted to incise and relieve the immediate surroundings of the fracture of a quantity of effused blood and serum, because of the great difficulty of drawing the upper fragment down to the base, on account of the pressure exercised by

this fluid. I was finally successful without incision. This experience, however, together with other cases, suggests that in some cases it would not only be proper, but absolutely necessary, to cut down and evacuate the effused fluids. When this is done it would be but a very small additional step to drill the fragments and wire them together, and I believe this to be the proper treatment in some cases.

Fractures of the olecranon rarely require anæsthesia for adjusting the fragments and holding them in place. The forearm must of course be put in extension, then careful manipulation will in nearly every case—except where there is a severe laceration of the triceps tendon and lateral tilting of the detached fragment—succeed in bringing the upper fragment down to its base. Then while it is firmly held in position with one hand, the other should adjust a compress of absorbent cotton or several thicknesses of a soft woolen cloth (a piece of old blanket will do) just above the apex of the process, then transfer the retaining hand to this, hold it firmly in place, and then fix it by strips of strong adhesive plaster laid on obliquely from above downward. Then another set from below upwards may be employed, the two together forming a sort of figure eight. The limb should not be completely encircled by these strips, and care should be used not to lay them tightly over the anterior surface of the joint in a circular manner, as they will compress the veins and cause a great deal of pain and produce great œdema of the forearm and hand. After the strips are fixed and the compress is in proper place, bandage the extremity from the fingers to the anterior fold of the axilla with a flannel bandage, and then put on a plaster-of-Paris splint. If all goes well this splint should remain undisturbed for two weeks, then be carefully cut, removed, the fragments examined, and if there is still a little separation, the compress may be removed and readjusted so as to bring the upper fragment further down, and

the plaster splint reapplied. The splint should be continued for six weeks, but it should be removed every week or ten days after the first removal for the purpose of inspecting the condition, bathing the limb with alcohol, with the employment of gentle massage. Passive movement should be done very gently, and carefully after six weeks, gradually increased daily, and massage continued. The union will be ligamentous, but the function is, as a rule, good after these fractures.

While the separation in the majority of cases is distinct, in other cases the fracture occurs but the tendon of the triceps is not torn across, and in these cases no appreciable separation takes place; it is only by careful manipulation that decided crepitus may be elicited and the nature of the injury determined. In these cases a well-fitting plaster-of-Paris splint, which should hold the forearm in an extended position, is all that is necessary. When the separation is very great and a persistent spasm of the triceps muscle prevents the upper fragment from coming down, an anæsthetic should be employed, and as there is usually a great deal of effusion, I believe the proper treatment for these cases is, as I said before, incision, evacuation of the blood and serum, and wiring together the fragments. This operation must be done under very careful asepsis, and it is necessary to employ gentle passive movements much earlier (after three weeks), else complete flexion may not be possible afterwards.

A practical point in adjusting the position of the forearm while putting on the plaster-of-Paris splint is to see that the hand shall be in supination. This position brings the olecranon more truly in the axis of the olecranon fossa; if there be a laceration of the external lateral ligaments of the elbow-joint at the time of the injury, pronation or semi-pronation may swing the lower fragment (the upper end of the ulna) out of its true position and thus cause vicious union. This position is very tiresome, however, and

I think it will do no harm and greatly add to the comfort of the patient, if at the first removal of the splint (two weeks after the fracture) the hand be put in semi-pronation and be retained after this in this position.

Fracture of the Coronoid Process.—The coronoid process has such a ma sive base and it is so deeply located, it is so well protected and is exposed so little to blows and violent strains, that it is very rarely fractured. Except as an accompaniment of backward dislocation at the elbow-joint, this fracture is exceedingly rare. I have never seen an uncomplicated case of fracture of the coronoid process. Theoretically, the treatment should be manipulation during flexion, to restore the fragment which may be drawn upwards. As it is the apex which is broken, except in severe crushes, this drawing up must be very slight, as most of the fibres of the brachialis anticus muscle are attached to the base of the process and are separated from the apex by the anterior ligament of the elbow-joint. This small fragment may possibly get between the anterior part of the articular surfaces and thus give great trouble. This should always be thought of in fixing an elbow-joint after reducing a backward dislocation. When touch and the fluoroscope show that the fragment has been properly reduced by manipulation, the forearm should be fixed at a right angle with the arm by a plaster-of-Paris splint. Early passive movements should be employed, viz., after two weeks. After this the treatment should be chiefly graduated passive movements every day, with massage to the forearm and elbow joint. The forearm may now be without a splint, the elbow being stiffened by the application of adhesive plaster strips laid on so as to prevent much movement at the elbow-joint. Extreme flexion may not be possible after this fracture. Otherwise the function should be good.

Fracture of the Shaft of the Ulna.—Fractures of the shaft of the ulna are not nearly as common as

fractures of the radius, because, doubtless, the hand by means of the wrist-joint is connected directly with the radius and only indirectly, by means of a triangular pyramid of fibro-cartilages, with the ulna. So the strain and force of the indirect violence, which comes so frequently in falling and catching on the hand, is felt especially by the radius. Fractures of the shaft of the ulna usually occur near the middle of the bone and are usually oblique. The shaft of the ulna may present the rare variety of fracture called "green stick fracture." I have seen one example of this in the case of a child. In replacing and treating fractures of the ulna it should be remembered that the shaft of this bone is not straight, but that it bows toward the external aspect of the forearm. It is, therefore, exceedingly difficult to reduce a fracture when one of the displaced fragments is in the interosseous space. Extension will do no good, that is to say, ordinary traction will not; one must employ direct manipulation under anæsthesia, and sometimes firm bending towards the radial side together with manipulation. After the fracture is reduced, simple straight, inflexible pieces of board are not proper splints, because the ulna is quite superficial and the pressure coming especially at the middle where it is bowed most, is apt to drive the ends forward and cause overriding of the fragments. Simple circular constriction and fixation, such as is obtained by the the ordinary bandage method of applying plaster-of-Paris splints, is apt to drive the ends toward the radius into the interosseous space. In the cases of antero-posterior displacements, the patient may be anæsthetized, if there is much overriding, the forearm bent to about a right angle, the hand supinated, and the ends of the fragments gently but firmly pressed into place by direct manipulation. A flannel bandage may now be applied lightly from the fingers to the elbow, and over this and immediately over the fracture, two antero-posterior splints of flexible wood or tin be

moulded on. They should be wide enough to reach quite to the lateral surfaces of the forearm, in order to prevent the plaster-of-Paris bandage, which should then be put on, from constricting the forearm and thus pressing the fragments into the interosseous space.

Another good dressing is the application of plaster-of Paris after the Bavarian fashion; namely, a number of layers of crinoline cut to fit accurately on the anterior and posterior surfaces of the forearm, then soaked in a creamy mixture of plaster-of-Paris, and laid on, accurately fitted to the forearm, and held in place by a circular bandage at the wrist, in the mid-forearm, and just below the elbow-joint,until they are dry. These splints should remain on two weeks and then be removed, the fracture examined, the forearm washed off with alcohol, and a fresh and light plaster dressing applied while the hand is held in semi-pronation. I prefer supination at first because pressure may be made more directly on the bone and the interosseous space is widest in this position. It is tiresome, however, and as soon as union has begun the position may be changed to the more comfortable semiprone. Splints should be worn for three weeks if all goes well, and then gradual and graduated passive and active movements begun.

If the fragments are decidedly displaced into the interosseous space and especially if one fragment touches the radius, I think the proper treatment would be incision, under most careful asepsis, careful adjustment of the fragments, and wiring them together. If this is not done there will be great danger of the displaced fragment remaining near the radius, adhesion is apt to take place, and not only a vicious union and a distorted member result, but a decided impairment of the functions of the extremity, as pronation and supination will be almost impossible. The recommendation to employ wedge like splints or compresses between the bones of the forearm, after fractures of

the bones of the forearm, may be a very mischievous one; these dressings are painful, usually produce much œdema, and can rarely be depended upon of themselves to keep the bones asunder. If the fragments persistently encroach upon the interosseous space the proper treatment, nowadays, is certainly the open method, viz., wiring or fastening the ends together by an operative procedure.

FRACTURES OF THE RADIUS.

1. Fractures of the radius may be divided for practical purposes into (1) Fractures of the upper extremity; (2) Fractures of the shaft, and (3) Fractures of the lower extremity of the bone.

1. *Fractures of the Upper Extremity of the Radius.*—Simple uncomplicated fractures of the upper part of the radius are rare. The ulna is much oftener broken near the elbow-joint, whereas the radius is oftener broken near the wrist-joint. The relative fixidity of the upper and lower ends of the bones probably explains this. As a complication of the fractures of the condyles of the humerus fracture of the head and dislocations of the head of the radius are quite common, as was stated in writing of the fractures of the condyles.

Simple fractures of the head of the radius are commonly due to some form of direct violence; the line of the fracture is usually oblique; unless the orbicular ligament is badly torn there is usually very little appreciable displacement. What little displacement occurs is usually upwards into the elbow-joint. For this reason this fracture may be a very disagreeable injury, as it may result in very materially lessening the function of the elbow-joint.

The treatment consists in carefully adjusting the detached fragment by manipulation. This can best be done while the forearm is in extension. Then carefully hold the fragment in place while an assis-

tant flexes the forearm to a right angle with the hand in semi-pronation. To prevent the fragment from slipping upwards place a compress of absorbent cotton in the flexure of the joint, apply a posterior angular splint, and bandage the extremity firmly to it while the assistant grasps the elbow-joint and holds the fragment down under the compress. A plaster-of Paris splint put on with the same precautions and in the same position is also a very good dressing.

I am convinced that absolute immobilization for three weeks is best if good coaptation of the fragments has been obtained. After this, daily passive movements and massage should be gradually and systematically employed. In case the fragment cannot be replaced nor be controlled, I would recommend excision of the fractured head under strict aseptic precautions; unless this be done the elbow-joint is apt to lose much of its mobility. If the orbicular ligament is not badly lacerated, pronation and supination will be fairly good without the fragment which is detached, and which will be removed by excision.

Fracture of the Neck of the Radius.—Uncomplicated fractures of the neck of the radius are extremely rare. I have no record of any case that was undoubtedly such a fracture. I have seen one case which I thought was a fracture of this kind, but as there were no X-rays at that time available to prove the correctness of the diagnosis, I was not sure of it. Theoretically, fixation of the forearm and hand in complete supination, in order to correspond with the turning of the upper fragment by the biceps, would seem the proper position. I believe flexion of the forearm to a right angle would help steady the upper fragment, and is better than the straight position. Plaster-of Paris makes an ideal splint for this injury.

2. *Fracture of the Shaft of the Radius.*—Injuries to the forearm, except direct violence, rarely fracture the shaft of the radius. These fractures are not par-

ticularly common therefore.* When both bones are fractured, the shaft of each is commonly involved; the radius usually below the tubercle and the ulna some two inches further down. As a single fracture, breaks of the shaft of the radius are comparatively rare—that is in my experience.

If the fracture occurs below the middle, the classical deformity of a tilting up of the upper fragment by the combined actions of the biceps and pronator radii teres, and a tilting downwards of the lower fragment by the pronator quadratus and the supinator longus ought to take place. I have found that these theoretical displacements are greatly modified in the actual occurrence. It all depends largely upon the force which produced the fracture. In many cases, one or more of the muscles are badly lacerated, and do not act in their normal axis, and not powerfully; or a muscle may be almost completely paralyzed, and not balance its antagonist at all. In some cases, therefore, the upper fragment may be in a supinated position, and in others in a pronated position; just in this fact lies the difficulty of treatment. It is almost imposible in a muscular forearm to know by palpation whether the upper fragment is in supination or pronation. As the biceps is less apt to be injured severely in an accident which has resulted in a fracture of the shaft of the radius, and as it is one of the most powerful of the supinators, it is usually best to presume that the upper fragment is supinated, at least slightly. The pronator radii teres is much more apt to be injured, and to act feebly or not at all. If the end of the upper fragment is tilted decidedly upwards, the pronator and supinator about balance one another, and the fragment is midway between pronation and supination. Having by careful examination determined the exact position of the upper fragment, the problem is to bring by manipulation

* I am aware Mr Gray, in his work on Anatomy, says fracture of the shaft of the radius is much more common than fracture of the shaft of the ulna; in my experience this is not so.

the two fragments in exact apposition and hold them there. Extension by traction will help very little. Flex the forearm, and try by first supination, and then by gentle pronation to bring the fragments exactly end to end. (The manipulation will usually require an anæsthetic). When apposed, stop immediately any further movement. Put on two thin wooden splints anteriorly and posteriorly. See that they are well padded, and that they reach from the base of the styloid processes to about an inch below the flexure at the elbow-joint; bandage these firmly in place with a flannel bandage, and then apply a light plaster-of Paris bandage from the palm of the hand to the elbow. It should not go up so high as to seriously interfere with the movements of the elbow. After two weeks have elapsed this dressing should be cut and the member examined carefully to see that the fragments are in good position, as there is apt to be a little lateral displacement. If this is external it may be overcome by direct pressure gently applied. If it be towards the interosseous space it is a hard case. Sometimes changing the position of the hand, for instance, from semi-pronation to supination, will overcome it. If it does not, nothing will avail but an incision, direct replacement and holding the fragments with pins, wire, or some other mechanical contrivance. I have tried interosseous pads, compresses, and almost every conceivable external appliance with very little result in the way of proper correction of the displacement. If it is not corrected, the movement of pronation and supination will be very seriously impeded, perhaps be entirely prevented. If the fragments are found in good position, the same splint may be reapplied, and held in place by a roller bandage, or a fresh one applied for another week. Then the splint may, as a rule, be removed, and gentle movements be begun and practiced daily and increasingly. The forearm should have a light bandage, and be carried in a broad sling for at least another week.

Fractures of the Lower End of the Radius.—By far the most common fractures of the bones of the forearm are those at or near the lower end of the radius. Colles' fracture, or fractures similar in point of location and not in displacement, are more frequent than Barton's fracture. I am inclined to think from my own experience, however, that many of the so-called "sprains" of the wrist-joint are fractures of some part of the rim of the lower end of the radius, together with a tearing off of a part of the anterior or posterior ligament of the radiocarpal joint. One should be very careful in examining injuries about the wrist-joint, in order to recognize or exclude these small fractures. It makes considerable difference in the prognosis if a fracture exists; the treatment is practically the same, namely immobilization in both cases, *but* in case of fracture it is absolutely important to know that a small piece of the rim of the radius has not slipped into the joint and is not lying between the articular surfaces.

For convenience in suggesting treatment, and for all practical purposes, fractures of the lower end of the radius may be divided into two classes (1) the Colles' fracture and (2) all other fractures.

1. *Colles' Fracture.*—The displacement producing the peculiar "silver fork deformity" may be taken as the differential point between Colles' and other fractures. In this fracture the radius is not only broken across, but the lower end of the ulna is dislocated and the cartilage which intervenes between the end of the bone and the carpal bones (the triangular articular cartilage) is wrenched away from the end of the ulna. Kahleys (quoted in *The Medical News*, March 5, 1898, p. 306, from *Deut. Zeitschrift fur Chirurgie*, vol. XLV., p. 531) found in forty-eight cases of fracture of the lower end of the radius examined and photographed by X-rays that 78 per cent. of all the cases also had a fracture of the *tip of the ulna*. I

have not been able to verify this observation, but in the great majority of my cases of Colles' fracture dislocation of the triangular cartilage had occurred. In treating these cases this fact must be borne in mind.

In reducing a Colles' fracture it is almost always necessary to use an anæsthetic. Primary anæsthesia is all that is necessary, as a little deftness of manipulation will reduce the fracture readily and rapidly; no anæsthetic will be required while the fixation apparatus or splint is applied. When once reduced the fracture is not inclined to slip out of place again unless great carelessness of manipulation is shown by the surgeon.

The usual displacement of the lower fragment is upward, backward and outward. The spasms of the muscles clinch the displaced fragments in such a position that it is very difficult to restore the proper position by simple extension in the normal axis of the limb. In this fracture especially, it is important to remember the cardinal rule for extension in reducing fractures, viz., *always begin by extending in the axis of the displacement.* In this case the extension should be downward, forward and inward. This extension may be done very rapidly and be greatly facilitated by first increasing the deformity by pressing the wrist and hand downward, thus unlocking the fragments; then by a quick pull in the proper direction (as indicated above) the fragments will come into place, *as a rule.* According to Kahleys' observation about an equal number of the Colles' fractures are oblique and transverse, with reference to the axis of the radius. In two-thirds of the cases there was but a single line of fracture. Of the cases in which more than one line of fracture existed, in three-fourths the lines of fracture were Y-shaped. So, while, as I said, *as a rule* the above manipulation will restore the fragments to good apposition, if the fracture be Y-shaped it may not do so. In this case extension should be done by an assistant in the proper direction, and the operator

should carefully palpate the seat of fracture, and when he finds extension suffices to disengage the fragments he should have the hand of the patient elevated to its proper position and at the same time press the fragments into place with his hands.

Transverse fractures and Y-shaped fractures remain in place as a rule, when thoroughly reduced, without any sustaining apparatus or manipulation. Not so with oblique fractures, however. These last require extension kept up until some fixation splint has been applied. It is therefore very unsafe teaching to declare, as some modern writers have done, that Colles' fractures require no fixation other than a strip of adhesive plaster or a sling. While this may be in a general way true of classically typical Colles' fractures, it is decidedly not true of many fractures at the lower end of the radius which are ordinarily called Colles' fractures, and which are frequently treated by physicians who do not recognize the points of nice distinction, and who go according to the dictum of their favorite authority in their treatment. In my judgment it is far safer to teach that it is always best to fix the bones and the wrist-joint carefully, after it has been determined that the fragments are in their proper place, and to keep them fixed for at least two weeks. I am thoroughly in accord with the idea that simple apparatus should be employed—the simpler the better if it will do its function properly.

Another point is to put the hand in proper position before the fixation apparatus is applied. The obtuse angle at the ulno-carpal junction should never be forgotten. Semipronation and a tilting of the fingers and palm towards the ulna side of the forearm is the proper position. This may be exaggerated too. The skiagraph marked No. 15, will show very good examples of over-correction on the right side and under correction on the left side in a person who had Colles' fracture of both forearms at different times. In the first case the styloid process of the ulna is unduly pro-

minent on the external aspect, and the articular cartilage is jammed over towards the lower fragment of the radius and interferes with pronation. In the second case (on the left side) the lack of correction has left the styloid process inwards and forwards near the pisiform bone, and the articular cartilage seems to have disappeared. For a long time supination was very weak and painful in this extremity and the deformity is quite marked.

For the fixation and dressing of these fractures, as in all other fractures, no set procedure nor specific splint will serve in every case. Antero-posterior flat splints of thin pieces of board will serve in many cases. Compresses over the ends of the fragments are rarely necessary. Plaster-of-Paris furnishes as nearly as possible an ideal dressing for these cases, and I have found it more generally adaptable than any other material or splint.

Whatever apparatus is used, the fingers should be left free, so that the patient may begin passive and active movements of the fingers very early, and persist in exercising them, so that no stiffness shall result from adherent tendons. After two weeks the original dressing should be removed, the parts inspected, and passive movements made at the wrist-joint. From this time on any light simple dressing will suffice. After three weeks, as a rule, splints may be discarded and active movements be gradually and persistently begun. Pronation and supination will be the most difficult movements to reacquire. It will not be wise to apply too much force in these movements at first. Gentle, gradual and persistent practice is the proper method.

2. *Other Fractures at the Lower End of the Radius.*—Barton's fracture I believe is commoner than was formerly supposed. As there is usually comparatively little displacement and the fragments are usually within the lacerated anterior or posterior carpal ligament crepitus is rarely obtainable; by simple palpation and manipulation it would pass unnoticed.

The use of X-rays will undoubtedly do much toward determining this matter.

Kahleys in his examination found that eleven per cent. of the cases had fractures of the styloid or a part of the articular process only—whereas only two cases were found which had complete fracture of the whole thickness of the bone without displacement (fissured fractures). This bears out the statement made at the beginning of this article.

All so called dislocations at the wrist-joint, and severe sprains at the wrist-joint ought to be very carefully examined to exclude a fracture of the lower end of the radius. I have seen several cases which upon careful exploration were determined to be fractures as well as sprains and dislocations.

Fissured fractures and Barton's fractures, or variations of Barton's, usually have very little displacement. The one exception may be a fracture of the posterior rim of the articular end of the radius, produced by falling on the dorsum of the hand, or by a similar violence. In these cases the bit of loose fragment may slip between the articular surfaces and give great trouble, not only to replace it, but also to retain it in place. In cases in which it is very difficult to manage this little fragment, I think the best treatment would be to incise and remove the bit of bone under most careful asepsis.

Fractures without displacement require simple fixation. In these cases a cuff of adhesive plaster, of moulded leather, or plaster-of-Paris is all that will be required. Passive movements may be begun in two weeks, and the same after-treatment be followed as after Colles' fracture. Soreness and aching about the joint is very apt to be felt for a long time after a fracture involving the articular ends of the bones. Daily hot baths of hand and wrist followed by massage, I have found very useful in such cases. In rheumatic and gouty subjects it is important to give internal treatment directed toward a correction of the lithiasis

in connection with local treatment. In cases of marked rheumatic gout a very guarded prognosis should be given as to the time of absolute recovery and usefulness of the member.

FIG. 11. Fracture of Shaft of Ulna.

FIG. 12. Fracture of Shaft of Ulna ; Dislocation of Head of Radius.

FIG. 13. Fracture of Shaft of Radius.

FIG. 14. Colles' Fracture.

FIG. 15. Over-corrected and Under-corrected displacement of Colles Fracture.

FIG. 16. Old Unreduced Colles' Fracture.

FRACTURES OF THE BONES OF THE HAND.

1. *Fractures of the Carpal Bones.*—Simple uncomplicated fractures of the carpal bones are very rare. I have no record nor recollection of ever having seen such a fracture. As a result of direct violence it is possible that the carpal bones might be fractured without any serious wounds of the soft tissues, but I have never seen a case. As a feature of extensive crushing of the hand, as for instance from injuries produced by drawheads of freight and coal cars when brakemens' hands are caught between them, or cogwheel or flywheel injuries to the hand, they are not uncommon. In such cases the fractures of the carpal bones are not the chief features of the injuries, and as a rule these extensive crushes demand excision of the crushed bones, or amputation of a part, or the whole hand.

Theoretically there should be very little displacement of fragments in simple fractures of the carpal bones. The treatment should consist in immobilizing the hand from the fingers up, as well as the wrist-joint. Some form of plastic splint would serve best I think. The only complication to be dreaded is the persistent soreness and long continued pain which is apt to be the result of any fracture about the wrist-joint in old subjects, or in those who have a gouty or rheumatic diathesis. This soreness or pain prevents proper motions being instituted after the fragments have had time to unite; this in turn is apt to result in a stiff wrist-joint, as well as the glazed atrophic and dreadfully painful condition one so often sees in the fingers of individuals who have had rheumatoid arthritis in the joints of the hand.

2. *Fractures of the Metacarpal Bones.*—Direct violence usually causes fractures of the metacarpal bones, though they also occur from falling on the clinched fist, or by striking the fist against a hard surface. Falls and prize fighting are most apt to

cause these fractures, when they are produced by indirect violence, therefore.

The metacarpal bones are not infrequently fractured, and very commonly are separately fractured, that is, only one bone is fractured. These fractures are very difficult to treat so that perfect union without appreciable deformity shall result. I believe two factors are chiefly concerned in the cosmetically bad results usually obtained, viz: First, improper reduction, and second, unscientific splinting or dressing. These statements sound puerile and a little absurd, no doubt, because the two causes given are those which almost invariably produce deformities after fractures. What I mean to state is, that when one thinks he has reduced the deformity and has properly apposed the fragments he has, in eight cases out of ten, done nothing of the sort; then, in many instances the surgeon forgets the anatomical configuration of the metacarpus, and puts on flat splints or a dressing in a manner which indicates that he thinks the tarsus is flat, when actually it is not so at all.

First, then, be very careful to reduce the fracture. This must be done almost wholly by manipulation. Extension by pulling on the fingers of the patient—unless the interossei muscles concerned have been badly lacerated, will do no good. The displacement is almost always antero-posterior. Commonly the lower fragment projects on the dorsal aspect, and the upper fragment on the palmar aspect. Extension in the line of the normal axis of the bone, as in Colles' fracture, simply clinches the fragments tighter together. One should extend in the axis of displacement and even exaggerate the deformity at first. This manipulation may be done by grasping the upper fragment near the fracture and holding it as firmly as possible with the fingers of one hand, then catch the lower fragment near the phalangeal joint and bend the end of the bone downwards toward the palm until the deformity is considerably increased; now

draw firmly with this hand upon the lower fragment in this axis until the fractured and displaced end is seen to move downward under the skin; now while still drawing firmly slip the upper hand rapidly to the seat of fracture, and press the two fragments respectively upwards and downwards, and as soon as they move a little apart bring the phalangeal end of the bone rapidly upwards to the normal axis. This ought to reduce the fracture; if it does not then the manipulation must be tried again and again, if necessary, until the ends actually meet and do not simply bend down into the palmar muscles in their still clinched and displaced condition, as they will do with the old extension method.

Secondly, in applying splints or any fixation apparatus, it must be borne in mind that the metacarpus, especially in hands of the better class of people who are accustomed to wearing snugly fitting gloves, is concavo-convex, antero-posteriorly, and oval in outline from side to side. As the palmar side is concave splints applied to this surface should not be flat, but be built up to fit accurately into the concavity of the bone, so likewise the dorsal splint must be curved in order to fit the convexity of the dorsal surface.

I believe it best to apply a narrow properly adjusted splint to the individual bone or bones fractured, and then a fixation apparatus of a plastic kind to the whole region, including the fingers to the second phalangeal joints. Hard rubber strips, or aluminium strips or stout strips of tin, all of which may be curved to fit accurately, should be applied on the dorsal and palmar surfaces of the fractured bone, while an assistant holds the fragments in accurate position. These strips should be broad enough only to extend a little beyond the border of the individual bone and be held firmly and snugly in place by an immediate application of surgical adhesive plaster laid on in an oblique manner, not transversely around

the palm. Over this the whole hand, from the second phalangeal joints of the finger to a point about two inches above the wrist-joint, should be enveloped in a light plaster-of-Paris, or liquid glass dressing. This dressing should be carefully molded to fit accurately by gentle manipulations while it is pliable, and no movement of the affected member be allowed until the dressing has hardened and set firmly. This dressing may remain on for two weeks; it should then be carefully cut off and the fracture be inspected. If the bones have been properly reduced, the ends will have united sufficiently to require only the small splints and the adhesive plaster for another week. After this all dressings may be discarded and the function of the hand gradually be resumed.

3. *Fracture of the Phalanges of the Fingers.*— These fractures are quite common nowadays. Fortunately surgical opinion has undergone radical change with reference to the treatment of these injuries. One reads with the utmost astonishment and concern the quotation of Boyer and Bransly Cooper in as late an edition of Hamilton's classic work on "Fractures and Dislocations" as the 1884 edition, to the effect that fracture of the distal phalanx of a finger makes amputation necessary; the half-hearted, hesitating and uncertain manner in which the author ventures to say that he believes this recommendation is too radical, nowadays, is curious indeed. It seems to me that any surgeon who would amputate a finger on account of a single fracture of one of the phalanges would render himself subject to a suit for malpractice. I will admit that it is frequently difficult to get a perfect cosmetic result after fractures of the last phalanx of a finger, but very rarely is the function of a finger seriously disturbed afterwards for the ordinary avocations, if careful treatment has been employed. One should hesitate long before amputating, and make himself quite sure that the phalanx or finger cannot be saved by waiting, after

most careful anti-and aseptic attempts to save every increment of the finger, even after severe crushes.

There is a slight antero-posterior concavo-convexity of the phalanges also. The bending is so slight however, that straight inflexible splints may be used in this region, if they are carefully padded. Malleable splints are better, however. In reducing the fracture of the phalanges, it is best to do it by manipulation. Usually the first steps should be an exaggeration of the deformity and extension in the axis of this exaggeration until the ends of the fragments are disengaged, and then a quick replacement of the finger to its proper axis while extending it. Fingers should be splinted and bandaged separately after a fracture of a phalanx. Be very sure that the restitution has been exact; having previously prepared a little splint just broad enough to reach well to the border of the affected finger; if *the splint be stiff pad it well,* apply to the palmar surface (if the fracture is nearly transverse a palmer splint alone will be necessary, if the fracture is oblique or comminuted, dorsal *and* palmer splints will be necessary.) The splints should accurately fit the natural curves of each individual finger, then hold them in place by strips of surgical adhesive plaster. It is not well to attempt to put a roller bandage on a fractured finger without first fixing the apparatus with adhesive plaster, because the splints are apt to be disarranged and be bandaged on in an improper position. If it is especially desired to have a perfect cosmetic result, the other fingers should also be fixed by some light apparatus, as very few adults can move their fingers separately. In using the uninjured fingers the tendons of the common flexor and extensor cause more or less movements of the injured phalanx. Perfect rest for the whole hand ought therefore to be assured for at least one week. Then fixation should be continued for the injured finger for two weeks longer. Then the dressings may be removed, and the joints be carefully

moved and a light dressing of adhesive plaster put on, and the finger be exercised lightly and gradually, daily. It will require some time for the finger to be restored to full usefulness. Careful and gentle passive and active movements should be sedulously continued until full suppleness has been restored.

FRACTURES OF THE BONES OF THE LOWER EXTREMITIES.

FRACTURES OF THE PELVIC BONES.

As one would naturally suppose, the exposed location of the ilium makes it most subject to fractures of all the pelvic bones. Next in order of frequency comes the pubis; very rarely the ischium is fractured.

Fractures of the Ilium.—Some form of direct violence, direct blows, squeezing between cars or heavy weights, usually cause fractures of the ilium. As a rule there is little separation of the fragments, except when the anterior superior spinous process is fractured. The crest is most apt to suffer. These injuries are not usually of a very severe character, and the prognosis is good unless the violence has been very great and multiple fractures have occurred. While the fragments, as a rule, are not much displaced the diagnosis of fractures of the ilium is not difficult. Careful manipulation will almost always elicit crepitus and great localized tenderness. In the absence of crepitus when localized tenderness and a little irregularity is found, it is best to treat the case as a fracture.

For fractures of the crest and body of the ilium I have usually found rest in bed on a firm, level mattress, with some broad bands of adhesive plaster around the pelvis, and a long lateral splint to immobilize the extremity on the affected side, suffice to assure a good result. Union takes place rapidly, and the patient may be allowed to be out of bed, as a rule, in four weeks. The upright position and walking

should be very gradually resumed after this. The adhesive strips about the pelvis, or firm bandaging should be continued for two weeks, at least, after the patient is allowed out of bed and begins to use his lower extremities again.

Fractures of the anterior border of the crest implicating the spinous processes are sometimes followed by wide separation of the fragments. In some cases, especially comminuted and compound fractures, I have observed wide separation of the muscles and fibrous tissue lining the inner surface of the bone; in these cases very disagreeable hemorrhage is apt to occur and the blood lodges along the inner plane of the ilium. This hæmatoma takes a long time to absorb, and by preventing the soft tissues from reaching the bones, it interferes seriously with the re-establishment of immobility of the fragments, and delays union. In these cases I have found trephining of the ilium, thorough evacuation of the hæmatoma and drainage, under careful asepsis, most useful in facilitating the treatment, relieving pain, and shortening the time of disability.

Simple fractures of the anterior superior spine require relaxation of the sartorius and rectus muscles by flexing the thigh, careful manipulation to bring back the displaced lower fragment; and while an assistant holds this fragment in place, with a compress of cotton wool over it, apply a strip of adhesive plaster in a crescentic manner from the abdomen downward and outwards a little below the process, and then upwards and backwards along the dorsum of the ilium. After this is made fast, apply a second strip in the same shape, only beginning in the opposite direction, namely from the dorsum of the ilium downward and forwards, then upwards and inwards towards the umbilicus. These strips help to sustain the lower fragment and prevent any considerable separation from its former attachment. While the assistant still maintains some pressure over the pro-

cess, try to gradually bring the thigh down to a horizontal position. If this can be accomplished without displacing the fragment, fix the thigh, or rather the whole extremity, by a long lateral splint, or plaster-of-Paris bandages. In case the fragment is persistently displaced when the thigh is brought gradually downwards towards the level, it is best to retain the flexed condition by the application of some malleable splint applied along the anterior surface of the leg, thigh, and groin, and to hold it in place by plaster of Paris bandages. A Nathan Smith wire splint or a strip of tin will serve very well. Provision should always be made in applying such an apparatus as this to suspend the extremity, for the position becomes very irksome and disagreeable without proper support. Suspension furnishes the best means for supporting the limb.

Fractures of the anterior spine require a longer time "in splints" than fractures of the crest or dorsum. About six weeks ought to be allowed for these. Great care should be exercised in beginning active movements, and full activity be graduated and very gradually resumed. A support of a band of elastic webbing, in case of the crest or body of the ilium, rather wide, and in case of the anterior spinous process, narrower, worn about the pelvis for several weeks, will be of service and give confidence and comfort to the patient.

Fractures of the posterior processes are rare, unless the fractures involving the posterior portion of the crest which extends into the sacro-sciatic notch be classed as fractures of the posterior processes.

These fractures should be treated on the same lines as those of other portions of the crest, only bearing in mind that there is a tendency to a displacement downwards and backwards, and in dressing them a firm support in the form of a well-filled jute pad should be placed below the process and be bandaged firmly in place by the bandage, which will also hold

the splint in place. Plaster-of-Paris makes the best dressing in these cases.

The one complication to be feared, both during and after fractures of the posterior parts of the ilium, is irritation or injury of the sciatic nerve and persistent pain in this nerve. For this reason great care should be exercised in trying to keep the fragments accurately apposed while the dressing is being applied, and while lying flat on the back will probably be painful at first, this position should, if possible, be preserved, as the pressure upon the mattress will help to hold the detached fragment in place. I think it wise to warn patients who have these fractures that they may have neuralgic pains during and for some time after the treatment of the fracture. I would advise active antilithic treatment for rheumatic and gouty subjects during their confinement in bed and for a short time after getting about, in treating these fractures

Fractures of the Pubis.—In my experience, and it has been my fortune to have had a number of fractured pubes to treat, the descending ramus has been most frequently broken, next the body, and rarely the horizontal ramus. I have no notes, nor can I recall ever having seen a separation at the symphysis pubis as the result of a traumatism, except in cases where the bony pelvis has been almost completely crushed. Some form of direct violence has been the cause of the majority of the cases I have had.

The diagnosis of fractures of the rami is usually comparatively easy, but some simple fractures of the body are difficult to make out.

As there is always grave danger to the bladder and urethra in severe fractures of the pubis the first measures, after recognizing the lesion, should be to ascertain the condition of these organs. Besides careful external palpation and rectal digital examination one should very carefully and gently explore the urethra. In these urethral explorations the strictest asepsis

should be observed. Besides washing, shaving, and disinfecting the pubic region and perineum, the anterior urethra, and of course the penis or vulva, should be thoroughly cleansed and disinfected before any attempt is made to pass an aseptic instrument. I prefer to use in these urethral explorations a large size silver catheter. I think, if the meatus and urethra are of normal size, nothing smaller than a No. 10 (English scale) catheter should be used for an adult. The reason for this is that with a small instrument one is most apt to follow into the cellular tissue any existing "false passage" caused by a rupture of the urethra, and besides may obtain a false impression from catching the end of the small instrument in one of the openings or depressions of a mucous gland. A third reason is that a large instrument, unless a stricture exists, is not so apt to wound the lining of the urethra. A bloody discharge from the urethra before the catheter is passed would suggest at once a laceration of the canal, but this does not follow necessarily after the passage of the instrument. If, however, the hemorrhage be free and a quantity of clotted blood be found in the urethra, the inference would be, of course, that the urethra was injured.

If it be ascertained that the bladder or urethra is injured the chief measures of treatment should be instituted to relieve this complication. This injury makes of the fracture a compound fracture of the worst type. A large number of observations have convinced me that normal human urine, *if not confined, does not materially hinder rapid healing either of soft or bony tissues.* The great desideratum, indeed the *absolute necessity*, is in these cases to obtain *perfect drainage* and to keep the wound clean.

For the last dozen years I have never hesitated in these cases to make a perineal section *at once*, and to drain the bladder through the perineum. The introduction of a soft catheter and its retention in the bladder through the urethra is insufficient as a drain,

and proves in most cases a dirty expedient. Hemorrhage sometimes is so severe as to require firm packing to stop it. It is usually impracticable to find and ligate the bleeding points. After the median cystotomy has been done and a tube introduced, iodoform gauze should be firmly packed into the lacerated perineal tissues about the tube. Then a firm external perineal pad with a hole for the tube to pass through should be firmly bandaged against the perineum, and the knees of the patient tied together.

If the urethra is torn entirely across, the operation for opening the bladder is, of course, imperative, and in these cases I prefer the perineal to the suprapubic route. It may be in some cases a little easier to do a suprapubic cystotomy, and then make a simple "buttonhole" drain from the perineum. I think, however, if one is fairly experienced in perineal cystotomy, and has not forgotten his anatomy, it is far better to make a median cystotomy without a guide, in order to drain thoroughly, and be able also to remove spicules of bone and detritus which are frequently lodged in the perineum. I have had occasion to do this operation in several cases with most gratifying results.

I recall one case of such extensive injury both to the bone and soft tissues, which was followed by rapid recovery, that I think it worthy of report.

A young man, nineteen years old, of stocky, muscular build, was caught in a railway switch, and while in a stooping posture, was struck by a locomotive. He was badly bruised nearly all over, and had some unimportant scratches and lacerations on his face and head. He was picked up and sent a distance of some twenty miles on the railroad to the hospital. When he arrived nothing had been done for him except the (formerly) inevitable drink of whiskey had been given him. His trousers were covered with blood and dirt, and the man was almost pulseless from loss of blood. Any movement of his lower extremities

caused him great pain in the pelvic region. Examination showed that his chief injuries consisted of a compound comminuted fracture of the ramus of the pubis and ischium on the right side, and the most extensive laceration and contusion of the soft tissues of the perineum and ischio-rectal fossæ I think I have ever seen. The immense lacerated wound extended from the lower arch of the pubis, through the *urethra, perineum, rectum and anus from the right into the left ischio-rectal fossa.* He had bled terrifically, and was still bleeding when he arrived. A rapid investigation, after hot disinfectant douching, showed that the urethra seemed to end in a ragged lacerated pouch under the symphysis. A finger in the torn rectum located the prostate gland near the upper angle of the rectal wound. With a finger on the apex of the prostate to guide it, a bistoury was passed into the bladder, and a free opening made by divulsing with the finger. A tube was introduced into the bladder, a number of detached pieces of bone were removed, and, as the jagged remnants of the external anal sphincter still held a semblance of anal puckering of dark blue tissue, the skin remaining undivided below and only punctured where the laceration extended into the fossæ, I immediately incised in the median line through the anus to the tip of the coccyx. Thus I obtained perfect drainage from bladder and rectum, though I completed the section which made of the whole region from the arch of the pubis to the coccyx an immense ragged bleeding chasm. I rapidly stuffed into this whole chasm a quantity of iodoform gauze, put on large pads of aseptic gauze and jute, strapped the knees together, and bandaged the pelvis. Though very weak for some days, the boy had no fever and very little suppuration. I repaired the rectum afterwards, and was also able to restore the continuity of the urethra. The patient made a good and rapid recovery. The only serious inconvenience which re-

sulted was an inclination to an anal stricture which required dilatation for several months. He not only walked without difficulty, but was able to return to his former avocation, viz., a brakeman on coal trains.

Another case which came under my hands, several years after the injury occurred, will illustrate the obverse of this treatment—namely treatment of a fractured ramus of pubis and ischium without perineal drainage.

A man about fifty years of age, who walked with some difficulty and very awkwardly, and who smelled most outrageously of decomposed urine, came to me for treatment of almost constant dribbling of very acrid and ill-smelling urine, sometimes retention of urine, and always more or less pain in the perineum. He was very weak, pale, and generally ailing. He had almost complete anchylosis of the right hip-joint. Examination showed an impermeable stricture of the urethra at its membraneous portion, but a small passage led out of the urethra towards the right and backwards. There was a large pyriform cyst under the adductor longus muscle just under Scarpa's triangle on the right side, and a gap in the ramus of the pubis, near the arch on this side; there was also an irregular mass of bone below the ramus of the ischium, which seemed to reach far back into the pelvis. After giving the man a little time to recuperate, under anæsthesia I made an exploration of the pelvis by means of a free median perineal section. I could find no prostate gland or only a little thickening where the gland should have been, and though I extended the dissection from the rectum upward, backward, and forward, until I reached the cellular tissue under the recti abdominales muscles, the only vestige of a bladder I found was a little pouch about four centimetres in diameter, in which I could not certainly make out any mucous membrane, and there was no urine in it. I made a continuous passage from the urethra to this little pouch, which was a little higher

up than the normal *bas fond* of the bladder, but occupied about the position of the anterior part of the bladder, if in the normal position. I left a soft catheter in situ. I now incised the cyst in the lower inguinal region which lay covered by the adductor longus and brevis muscles. From this there immediately spurted a quantity of fetid urine. Upon further investigation I found that this cyst was the *acting* bladder of the man, and that it communicated with the urethra by a long narrow tortuous sinus which when the muscles were in action, alternately closed and opened, and so pumped the urine almost continually, dropwise, out; when the man was sitting quietly, and especially when he was lying down there was almost a constant stillicidium of fetid urine. There seemed no proper mucous lining to this cyst, simply a fibrous wall with a lining of pus, urinary sediment, and detritus. I was not able to find the ureters and could not actually determine whether they emptied into the small pouch back of the symphysis or not. I cannot believe that they were carried down to the upper inner aspect of the thigh. The man gave a clear history of a severe injury to his pelvis, some years before I saw him. I concluded, therefore, that he had had a depressed fracture of the rami of the pubis and ischium, his urethra had been torn, perhaps the bladder also; he had had suppuration and sinuses following the injury, and the mucous lining of his bladder had either sloughed out (as I had seen in another case), or else it had been so compressed as to be useless as a reservoir for urine, and the urine had made its way to the inguinal region, and collected there and formed a cyst, which discharged by the devious sinus into the urethra. Most likely an immediate perineal section with free drainage might have saved this man from chronic invalidism and his most disagreeable condition.

After provision for thorough drainage is made when the urethra or bladder has been injured, and all

loose small pieces of bone have been removed, the hemorrhage should be thoroughly controlled. I think this may usually be done by packing the wound with gauze strips. If the packing be used, a tube should always be introduced into the bladder to carry off the urine, and thus prevent any damming back and gradual infiltration of the torn tissues.

Hemorrhage having been controlled one may turn his attention to the fracture itself. Ordinarily it will be best to fix the lower extremity on the affected side by a long lateral splint, which may also be used to steady the pelvis. Besides this long splint I usually employ some broad strips of bandage to hold the pelvis firmly. Adhesive plaster is apt to be loosened, it becomes very irritating to the skin, and makes it very difficult to keep clean, on account of the constant wetting from the escaping urine. For these reasons I think it is best not to use adhesive plaster. A Scultetus or many tailed bandage serves best. I think the separate bandage is not necessary when the fracture involves only the ramus, but when the body of the pubis is implicated it is necessary. In either case it gives a feeling of greater security and adds somewhat to the comfort of the patient. The dorsal position on a firm even mattress serves also in steadying the pelvis. This mattress should be perforated properly, or be in sections, so that the patient may have a bedpan applied for his evacuations without disturbing his horizontal position, and without the danger of wrenching the pelvis in the endeavor to adjust him to the vessel when he defecates. The patient should be kept in a horizontal position for at least four weeks, and then be allowed to recline a little (or be propped up in bed) a short time every day. In four weeks the long splint may, as a rule, be removed. The sitting posture may be allowed in simple fractures, usually in about five weeks. After six weeks in simple fractures, if all has gone well, the patient may, as a rule, be allowed to sit out of bed and gradually be assisted to

stand, and then very gradually begin to use his lower limbs again. The functional and cosmetic results after these fractures are usually good. Some slight irregularity in the outline of the bone may result, but, if it is not near the arch so as to possibly compress or push aside the urethra, it does no harm.

Fractures of the Ischium.—Very rarely is the body of the ischium fractured except when some great violence involves the acetabulum. In this case the other component segments of the os innominatum are also implicated—and the treatment may depend chiefly upon whether or not the head of the femur is dislocated. The ramus of the ischium sometimes is involved when the pubic ramus is broken. The treatment of these cases should be carried out on the same principles as recommended for fractures of the pubis. If the tuberosity should be comminuted, it would be possible that the internal pubic artery be torn, in which case it would be necessary to cut down upon and tie the vessel; otherwise, the treatment would be the same as for fractures of the pubis.

Fractures of the Acetabulum.—This fracture may occur when a dislocation of the head of the femur upward and inward takes place. One should bear this in mind when he has to treat a pubic or obturator dislocation of the hip-joint. In these cases it is usually the rim of the cavity which is chipped off. This detached rim may interfere very seriously with repositiom of the head of the bone, and afterwards endangers full mobility of the joint, as adhesions are apt to occur to the neck of the bone. Fissured fractures of the acetabulum may also occur. These involve the depths of the cavity and should be treated as fractures of the ilium. Disability and confinement to the bed and rest should be continued longer than in simple fractures of the ilium. Passive movement at the hip-joint should be begun in about four weeks and practiced daily—but very gently. The patient should not be allowed to walk for eight weeks,

and then very gradually and graduatedly. Restricted movements at the hip-joint are apt to be the result of these fractures.

FRACTURES OF THE FEMUR.

For practical clinical purposes fractures of the femur may be divided into: 1, Fractures of the Upper Extremity; 2, Fractures of the Shaft, and 3, Fractures of the Lower Extremity.

Fractures of the femur are common. In my experience the shaft is much more frequently broken than the extremities of the bone. In a series of 100 simple fractures of the femur I have treated in the hospital, 84 involved the shaft, 13 were fractures of the upper extremity, and 3 were fractures of the condyles. Of 10 comminuted and complicated fractures, 9 were of the shaft and 1 was in the condyles. Of 20 compound fractures 17 involved the shaft and 3 the condyles. In the whole series of 130 cases 110 involved the shaft, 13 were in the neck, and 7 were condyloid fractures.

Fractures of the Neck of the Femur.—Since the days of Sir Astley Cooper surgeons have engaged in a deal of hair splitting discussion as to the relative frequency of extra- and intra-capsular fractures of the neck of the femur. It seems to me to be an anatomic error to make this distinction in fractures of the neck. In young subjects, before ossification is complete, there is a comparatively narrow isthmus of bone between the epiphyses of the two trochanters, this is the angular union between the neck and the shaft of the bone. I would call this the trochanteric isthmus. This is partly within and partly without the capsular ligament; the neck proper is wholly within the capsular ligament. Before twenty years of age when a fracture occurs in the neck of the femur it is usually through the trochanteric isthmus, as this is the weakest point, but in later life, unless as the result of very great violence (and usually complicated

by other serious fractures), fracture at this point is very rare. I have seen but very few such fractures. I can recall but two. It happens that one of these two fractures has been received and examined during the preparation of this present writing. It is a case of an Italian, fifty-nine years of age, who by a landslip was carried down seventy-five feet into a slate quarry, and was almost smothered in a mass of stones and earth. He has a distinct fracture through the trochanteric isthmus. The other case was a boy seventeen years old, who fell into a pit about ten feet deep and also suffered a fracture through the trochanteric isthmus. Both of these fractures in-

FIG. 17. Fracture through the trochanteric isthmus.

volved the capsular enclosed portion of the neck, but extended also outside of the capsule (an oblique fracture, which is really a splitting off of the shaft with the greater trochanter from the neck and lesser trochanter of the bone.) See diagram Fig. 17.

It has always seemed to me, as I said before, that nearly all the cases of fracture of the neck I have seen have been intra-capsular, or through the neck proper. (See diagram, Fig. 18, *a* and *b*.) This question of location is material only as to treatment, as I think it should affect the treatment somewhat. The separation of the fragments in the intratrochanteric fracture is much more considerable, unless the fracture be impacted, than when the fracture is wholly within the capsule. In both cases the greater trochanter will be elevated and the foot everted, as a rule, but the elevation of the trochanter is much greater and the eversion much more difficult to overcome in the former, viz., fracture of the isthmus,

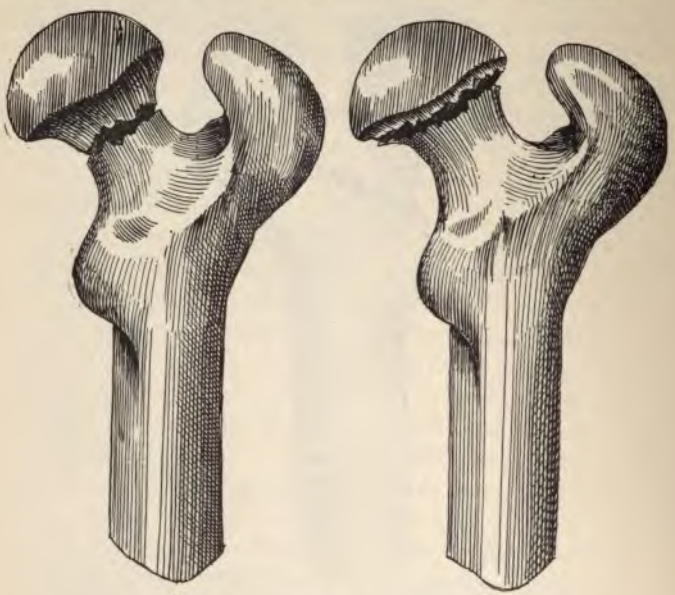

a *b*

FIG. 18. Fractures through the neck, intracapsular.

than in the latter or fractures wholly within the capsule. Another matter of special difficulty in fractures of the isthmus is the torn capsular ligament. The line of this fracture runs without the ligament

posteriorly, but just under and through the attachment of the ligament anteriorly. The whole anterior attachment of the ligament is, therefore, torn away, and the ileo-femoral ligament is also torn as a rule. These lacerated ligaments furnish many irregular clinging fibrous shreds which fall over the end of the upper fragment, and may absolutely prevent the bony surfaces coming together. If this occurs, "a false joint," and only fibrous union will result. Fractures of the neck proper may also cause laceration of the capsular ligament, but usually this is only in the nature of a few punctures of the ligament by some sharp edge of a fragment. As these fractures are usually nearly transverse, the ligament frequently escapes puncture altogether and remains practically intact, and the ligamentous feature will not complicate the treatment. If the line of fracture should go entirely outside of the lesser trochanter, instead of only through its base in a fracture of the isthmus, another complication would be the elevation and adduction of the upper fragment, that is the neck, by the iliacus and psoas muscles. I think, however, as a rule, the attachment of these muscles is torn away and they do not operate to produce the displacement.

Sometimes it is very difficult to differentiate fractures at the upper extremity of the femur. X-rays may be of great service, but it requires a particularly good apparatus and an experienced operator to make good photographs of the hip-joint and its immediate relations when the patient is fat or very muscular. If the age and physical condition of the patient will admit it is important in some instances to make a careful examination under general anæsthesia, and to put on the first dressing, after carefully adjusting the fragments, while the patient is thoroughly relaxed. It is important to make accurate immediate coaptation of the fragments, *if it can be done,* in these fractures. If, as is frequently the case, there is persistent and marked spasm of the muscles of the

thigh, it is almost impossible to make proper adjustment of the bones without an anæsthetic. In old and debilitated persons an anæsthetic is fortunately not so necessary, and one should hesitate to administer an anæsthetic in such cases. If, however, the patient's condition will admit of it, an anæsthetic will assist markedly in arriving at a proper and differential diagnosis, and make it possible to bring the fragments together.

FIG. 19. Shows the characteristic position of the foot only after fracture of the neck of the femur. Hip-joint brace applied about two weeks after the fracture.

In fractures through the isthmus the rule to make extension first in the line of the axis of displacement should be followed: when the greater trochanter is drawn down to its proper level the foot may be turned to its natural position. To make these manipulations a good strong assistant is necessary. He (the assistant) should grasp the foot under the heel and over the ball, with his hands in such a position that he

may even invert the foot, if necessary, without changing the grasp of his hands. The surgeon in charge should carefully palpate and manipulate the fragments at the seat of fracture, and direct the extension and rotation of the foot at the proper time.

Even more difficult than getting the fragments into apposition is the retention of them in their proper places. I have tried a number of splints of various constructions and designs, and have come finally to regard a proper extension and counter-extension apparatus without any splint to the hip and thigh as the best arrangement. I have made a modification of Volkmann's extension leg splint (see the accompanying illustration), which I use now in these cases. The transverse slabs are grooved and fit loosely upon hardwood parallel tracks which are planed to a fairly sharp edge above; these tracks are held fixedly by transverse pieces of flat hardwood.

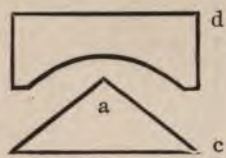

FIG. 20. *a*, *b*, *c*, indicate a section of the tracks which is seen to be triangular *d*, shows the groove of the slab.

The leg piece is similar to an ordinary Platt's leg and foot splint, except that the leg rest is longer in cases of fracture high up in the femur. This leg piece is screwed firmly to the transverse grooved slabs and thus moves firmly on what I call the "railroad" beneath, and the friction is reduced to a minimum. In applying the apparatus I prefer to apply adhesive plaster, strong moleskin plaster, directly to the leg; the strips should extend up above the knee in order to avoid the pain occasioned frequently by strong extension on the knee-joint, a roller bandage of flannel applied snugly over these strips should hold them in place. The leg splint is well padded, especially about the heel. There

is one point about padding a splint to make the heel rest comfortably which I find beginners never think of, and that is, that the padding should be not so much under the tendo Achillis and the point of the heel, as on the either side of the tendon and *under the malleoli*. Make the padding fit snugly in the designated places, and put only enough padding under the tendon and heel to prevent actual contact with the splint. Of course, the splint should be hollowed out

FIG. 21. Shows the extension splint looking at it from above.

to give place for the heel, and a little grooved to prevent pressure on the insertion of the tendon. This padded splint is bandaged to the foot and leg, while extension is maintained on the extremity, then the railroad placed properly and the track made to fit in the grooves on the transverse runners. Sufficient weight should then be applied to hold the trochanter major to its proper level. The pulley must be adjusted at such a height that the weight shall not

drag the foot downwards, but raise it a very little from the general level of the bed. I have found that strong adults require from ten to fifteen pounds weight to make sufficient extension. A very important complement to the dressing is the counter-extension band. I have found best a pretty broad soft perineal pad attached to either elastic cords or non-elastic bands, which in this last case must be carefully watched and frequently re-adjusted, always kept taut, and always fastened so as to make a constant pull outwards as well as upwards from the perineum.

FIG. 22. Shows the extension splint applied to the leg, in use.

(The accompanying illustration shows the whole dressing applied in actual service.) This apparatus is adapted to both forms of fracture of the neck, and has given me the best satisfaction in the majority of cases. It is simple, easily applied, and maintains its extension more constantly and more efficiently than any other dressing I have ever tried, and it gives most comfort to the patients.

If a rigid dressing is required by the exigencies of the case, and this will sometimes happen in very young, restless subjects, I think plaster-of-Paris dressing applied, while the patient is under anæsthesia, from the toes to the sternum, is the best. Manual or pulley

extension must be maintained until the plaster is set. While the majority of cases will have eversion of the foot after the fracture, a number will show inversion These cases with inversion I have found more difficult to replace and retain than the everted ones. The same methods will apply, however; only a little more manipulation and care should be exercised in "setting" the fracture.

Whether the foot be everted as is generally the case, or inverted, unless there be good reason to believe the fragments are impacted, the greatest care must be exercised to replace the fragments in as good apposition as possible and hold them there. As I said before, the replacement of the fragments is difficult, and the holding them in place is more so. I would like to emphasize the fact that a perineal counterextension upwards and outwards seems to me* a very valuable



FIG. 23. Another view of the extension splint.

part of an extension dressing. The normal lines, that is to say the lines which are normal for each separate individual, should be followed and preserved as nearly as possible. This can be obtained best by careful inspection, measurement and comparison with the uninjured extremity. In doing this, one should assure himself that no previous injury has caused a distortion of either extremity. The dressing proper for each case must, therefore, be carefully selected according to the indications of the individual under

*See accompanying photograph of extension and counterextension apparatus.

treatment. I believe, however, extension and counter-extension with a dorsal position on a firm, even mattress, will answer the requirements of the majority of the cases. The extending weight must be calculated for each individual case. Very muscular men will need twelve to sixteen pounds for a time at least.

While the foregoing may indicate the treatment for ordinary cases in vigorous health and old enough to be amenable to proper discipline, a variation must be made for the extremes of life, that is to say, for young children and old or feeble persons.

FIG. 24. This shows the extension and counter-extension dressing applied.

For children some form of double lateral splint, such as Hagedorn's, or Gibson's modification of Hagedorn's bilateral splint, serves best.† This apparatus should be put on while the child is under a general anæsthetic, and while the affected extremity is fully and forcibly extended. Great care must be exercised to properly support the pelvis, and to carefully fix both sides of the pelvis and both lower extremities fully and evenly. The counterextension should be divided between the axilla and perineum. In some cases the Sayre double wire splint or wire breeches may serve best.

In the case of old, feeble people (fractures of the neck are most common in these cases), long confinement to bed will not be tolerated. I would advocate

†See diagram.

in such cases a hip-joint apparatus similar to the Sayre or Hutchinson long hip-joint brace which is ordinarily used for coxitis. With such an apparatus well fitted I would permit the patient to be out of bed in a week's time. It is less important in these cases to attempt to obtain good union than it is to prevent confinement to bed. The shortened, horizontal necks of femurs in aged people rarely unite. I believe this is due not only to the fact that bony repair in aged people is less active, but especially because it is almost impracticable to preserve proper apposition of the fragments. This is because the fracture is usually transverse, and this straight across break in a horizontal short shaft connected at almost a right angle with the lever which must be used for extension and fixation, and a long lever at that, is most apt to have the bony surfaces escape from apposition.* The displacement causes pain, and this in turn results in restlessness, general irritability and physical debility. In order to save the life, or at least to prevent the hastening to the grave of such a patient, he must be taken out of bed and given fresh air, sunlight, and

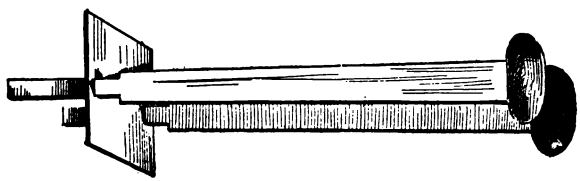

FIG. 25. Gibson's modification of hagedorn splint.

diversion. Impacted fractures of the neck of the femur should be handled so carefully that the fragments shall remain interlocked. The fixation apparatus without extension should be used, and very gradual correction of the displaced foot be attempted.

The length of time a patient must remain in bed and "in extension" must vary with each case. Two months is an average time for keeping the patient in bed. After this some hip-joint apparatus which will

† See diagrams, p. 126.

prevent any vertical strain on the neck of the bone should be employed for a month longer. Resumption of walking should be very gradual. Especial care should be exercised in going up and down stairs for some time. Early attempts at independent locomotion should be on a level, and the patient should not attempt stairs until he feels quite sure of his extremity.

Prognosis after fractures of the neck of the femur should, as a rule, be guarded. Young subjects rarely fail to have useful function after these fractures. Old subjects, however, rarely acquire full function of the extremity after fractures of the femoral neck. I am almost persuaded that the comfort and well being of an old patient is conserved by failure to obtain union of the fragments, and I doubt in many cases that it is proper to try to obtain union. Since it has been shown that absolutely detached pieces of bone will reunite after a fracture, if they are placed in good apposition with fellow fragments, and that fragments of bones may be transplanted with perfect success, the old idea that the fragments of a broken neck of the femur will not unite in old people because the inner, or head fragment, is so poorly nourished, must, I think, be entirely given up. The hip-joint cavity and the head of the femur, as every one knows who has ever done a hip-joint amputation for injury, is abundantly supplied with blood. The head itself, composed, as it is, of cancellous tissue, is a vascular reservoir. I cannot believe therefore that non-union results from insufficient nourishment of the head. I believe this lack of union is due to the great difficulty of keeping the fragments in apposition in old people. There is no reason to believe, and I know of no observation which showed that the capsular ligament of the hip joint contracts when senile shortening and *horizontalization* of the neck occurs. The capsule is, therefore, very lax and is much more apt to be injured than in early, vigorous adult life;

when the fracture occurs, shreds are more apt to fall between the fragments, and the roominess of the sac permits greater excursion of the lower fragment when any motion of the lower extremity takes place, and it also gives less lateral support to the fragments. The result is that it is much more difficult to retain the fragments of the shortened, horizontal neck together. Add to this the intolerance of pressure and extension of senile tissues, and it is not hard to believe that these fractures are seldom followed by bony union. If they do unite it is usually with much ensheathing callus, and a greater shortening of the neck. This causes symptoms similar to rheumatoid arthritis of the hip-joint, and many months if not the balance of the days of such a patient are full of suffering and distress. If the bones do not unite the

FIG. 26. Young Femur.

FIG. 27. Senile Femur.

ends of the fragments round off, atrophy, as is usual in ununited fractures, and while false mobility and an inclination to slip up on the part of the loose fragment may persist, pressure symptoms are rarely severe or even annoying, and with a well fitting hip-joint apparatus the person may walk and have a very comfortable existence. Hence I said that I doubt in many cases that we should attempt to obtain bony

union at the expense of long confinement, much suffering, and a probable greater lack of function and continued and persistent after-suffering from the pressure of a shortened, nodular and hypertrophied neck.

Neuralgic and rheumatoid pains are very apt to occur about the hip-joint after fractures of the neck of the femur, as stated above, on account of the pressure of the enlarged and frequently irregular, shortened necks, which is the result of the fracture when the bone unites. This is especially liable to follow in persons of gouty and rheumatic habits. In one case I treated, the pain seemed to be especially from pressure on the obturator nerve, in others the sciatic is affected. These pressure neuralgias are exceedingly intractable. If very severe and persistent, after a few months, I think an operation for removing possible irregularities from the bone and freeing the affected nerve should be performed.

Fractures of the Trochanters of the Femur.—Except as a part of a general crush of the upper extremity of the femur, fractures of the trochanters are very rare. I have seen one case, or at least I so diagnosed it, of independent fracture of the great trochanter. It was in an adult, and due to direct violence. I have never seen a case of independent fracture of the small trochanter. Theoretically the treatment should be immobilization of the affected extremity, with slight pressure directly over the fragment. In the case I treated there was no wide separation. I was able to bring the fragment down and hold it in place by a firm pad bandaged over it and around the pelvis. I added to this a long lateral external splint to immobilize the extremity.

Fractures of the Shaft of the Femur.—These fractures are very common and occur at nearly every age. They are usually oblique, though transverse, or nearly transverse fractures are not very uncommon. I have seen one green stick fracture of

the femur in a child, about five years old. Displacement of the fragments is usually marked. The lower fragment is nearly always drawn upwards and may be on either side or below the upper fragment. In the upper third the upper fragment is markedly tilted upward by the psoas and iliacus muscles; at other regions the displacement of the upper fragment may usually be disregarded in the problem of reduction and retaining the fragments. One should remember, however, that in fractures a little below the middle of the bone the adductors may prove troublesome factors by drawing the end of the upper fragment inward.

In these much dreaded fractures the most difficult variety to treat is the one through the upper third, a little below the trochanters. Indeed, in a strong muscular man it is almost impracticable to obtain union without some deformity and considerable shortening. These fractures must be reduced by finesse not by force.

First of all, the spasm of the powerful elevating muscles must be allayed. A full dose of morphia may sometimes do this, but if the patient will bear a general anæsthetic, ether should be used preferably, and the reduction accomplished by manipulation and extension, and the fixation apparatus applied during the absolute relaxation and unconsciousness of the patient. I have found that the straight position of the limb almost invariably causes a recurrence of the spasm of the iliacus and psoas, as soon as the effect of the anæsthetic wears off, and no ordinary retention apparatus will restrain the upper fragment; the chronic spasm causes continual and excessive pain, which in turn results in great restlessness and further displacement. Ordinary extension in a straight line will not overcome the tilting pull of the muscles. I nearly always resort to some form of double inclined plane in treating these fractures. This requires flexion of the thigh on the trunk and more or less flexion at the knee-joint. At the same time the hip-joint should

be immobilized and lateral deviation of the fragments prevented, while decided pressure should be kept on the anterior surface over the seat of the fracture. I think these several indications may be best and most comfortably obtained by a dressing similar to the Nathan Smith splint and bandage. Instead of the wire frame, I prefer a strip of flexible but fairly strong tin (roofing tin), broad enough to cover about one-half of the anterior surface of the thigh, and long enough to reach from the level of the umbilicus to the ankle. This should be curved so as to obtain sufficient flexion at the knee and hip-joints; it should be well padded, especially at the groin and over the fracture. Place the splint over the centre of the anterior surface of the limb, after a flannel roller has been applied from the toes to the level of the umbilicus, make it fit snugly down upon the upper thigh and in the inguinal region. Bandage this evenly and firmly



FIG. 28. Tin strips with loops of copper to be placed along the anterior surface of the groin, thigh and leg.—This should be incorporated in a snugly fitting plaster-of-Paris dressing.

to the limb and pelvis by a series of plaster-of-Paris bandages. The dressing of plaster should be thick and strong enough to thoroughly immobilize the hip-joint and knee-joint. The tin strip will cause sufficient pressure on the upper fragment to prevent a recurrence of the upward tilting, if the angle of flexion at the hip-joint is correct, and thoroughly relaxes the elevating muscles. Wire loops may be put around the tin strip for suspending the extremity. The extremity should *always* be suspended as soon as the plaster dries. This adds very greatly to the comfort of the patient and value of the dressing.

The fracture should be examined at least once a

week for three weeks, to be sure the fragments remain in place.

Another apparatus may be used in some cases consisting of a double inclined plane constructed of wood with a foot-piece. This should be reinforced by short apposition splints at the seat of fracture.

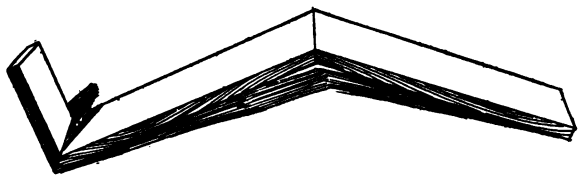

FIG. 29. Ordinary wooden, double inclined plan.

These last (apposition splints) will require readjustment every day. I consider this wooden apparatus much less efficient in every way than the plaster-of-Paris with the tin splint, and suspension. The fixation apparatus should be continued for six weeks at least, and then very gradual and gentle exercise of the muscles be made by massage and passive movements, while the limb is daily brought nearer to a straight or horizontal position. In eight or ten weeks the patient may be allowed to be out of bed and use a crutch. During this period a moulded splint of leather or felt carefully fitted to the upper thigh and pelvis will be of service.

It is very rare that fractures of the upper third of the femur unite without at least a little overlapping or a slight bow. This deformity ought, however, to be inappreciable except to the touch and careful inspection. Shortening of a half inch to an inch and a quarter must be expected.

Fractures of the shaft of the femur below the upper third may be treated by a variety of fixation dressings and splints. As a rule, however, the indication for an oblique fracture (oblique fractures are much the commonest variety, as I said before) are: 1. Careful reduction, under ether if necessary. 2. Continued

and forceful extension for a period of at least three weeks. 3. Short apposition splints or some local rigid application at the seat of fracture to prevent lateral deviations. 4. Even and snug bandaging with a stockinet or flannel roller to prevent swelling, and very careful adjustment of pads and apparatus to prevent irregular and local pressure.

Transverse fractures may be treated without extension, otherwise they require the same conditions of treatment as noted above for oblique fractures. I would especially urge, in reducing transverse fractures, the importance of *thorough relaxation of the muscles*; this can usually be obtained only by a general anæsthetic; also the great importance of extending the extremity in the line of the axis of displacement until the fragments are made to pass one another, and then bring the limb to its proper position as indicated by the uninjured limb and the contour of the broken femur. An assistant is absolutely necessary for extending the limb. The surgeon in charge should manipulate the ends of the bone during the extension and direct the extension in the proper direction. The importance of these two recommendations was illustrated by a case I was recently called to see in consultation. An old man of about seventy years of age had his right femur broken in its lower third by a blow from a crowbar. His physician had repeatedly tried to reduce the fracture and hold it in place, but without success. I was called in two weeks after the injury. I found the patient with a modified Bucks extension apparatus on, but the fracture, which was a transverse one, was unreduced and the ends overlapped about two inches. The lower fragment was drawn upwards and was posterior to the upper fragment. A glance at the uninjured extremity and an examination of the fracture soon gave me a clue to the difficulty. The old man was *bowlegged to a degree very rarely* seen nowadays. His physician, though

he had anæsthetized him, and had repeatedly attempted to extend the thigh, had *always extended in a straight line.* The result was simply to lock the fragments together, and apposition was impossible. I found the old gentleman so weak, and atheroma of his heart and vessels so marked that I did not dare to anæsthetize him. After getting plaster-of-Paris bandages ready I directed my assistant to make traction *downward* and *inward,* while I increased the inward direction by making a fulcrum at the inner side of the seat of fracture with my own hands *drawing forcibly outward.* These manipulations readily reduced the fracture, and while two assistants held the limb in proper position I applied a plaster-of-Paris splint at once, and held the limb until the plaster "set." The union was prompt and excellent.

FIG. 30. Shows double inclined position and suspension. In this case wire loops were not placed on the tin strips, extension and suspension obtained by bandages placed under the permanent dressings.

There are many and ingenious splints and apparatus for making extension and fixing the extremity for fractures of the shaft of the femur. Many of these are complicated, some cumbersome and difficult to apply, nearly all of them expensive, and *every one of them unnecessary as a rule.* I most heartily endorse

Dr. John B. Roberts' recommendation to greater simplicity in the dressing of fractures. In the great majority of cases extension by means of the apparatus I mentioned in writing of the treatment of fractures of the neck of the femur (See page 122) will be the best method of extending the limb. The counter-extension need not be, and *should* not be *upward* and *outward*, but simply *upward*. The extending weight must be sufficient to prevent overriding of the fragments. Short apposition splints applied at the seat of fracture should be added to this extension. This dressing will be found applicable and efficient in the majority of fractures of the shaft of the femur in adults. I have found it so efficient that I wish to note a few points which add to the comfort of the patient and value of the dressing.

FIG. 31. This shows the method of attaching the weight cord and the cross pin to the plaster strips.—It also shows the correct elevation of the pulley.

1. Counter extension from the perineum I think is far more efficient than raising the foot of the bed. 2. Some form of apparatus for reducing friction and for preserving the constant, even pull of the weight should be applied to the foot and leg up to the knee. I have found the modification of Volkmann's antifriction splint most useful and I can highly recom-

mend this (See photograph page 122.) 3. Use strong litharge moleskin adhesive plaster for making the extension, and see that the strips fit evenly and snugly on the leg, and that they extend a little above the knee, in order to prevent the heavy pull being felt at the knee-joint. 4. The ends of the adhesive strips to which the cord from the weight is usually attached by some form of wooden cross-piece, should be separated wide enough to prevent any pressure on the malleoli. The wooden cross-piece should be much longer than frequently employed, and instead of a slab of wood fastened into the plaster I prefer a wooden strip stuck into strongly made eyelets about one and a half inches from the end of the plaster. (See accompanying photograph.) 5. See that the padding about the heel shall not be under the heel itself, but under the malleoli and on either side of the tendo-Achillis. 6. Raise the pulley on which the weight cord is swung high enough to clear the heel just a trifle from the level of the railroad which supports the anti-friction splint. This will prevent the weight pulling the heel constantly against the splint, and thus causing much pain and a possible pressure sore.

Transverse fractures of the shaft require: 1, Most careful reduction; 2, local fixation splints or splint, and 3, careful immobilization. As was noted in the foregoing pages, the first indication, namely, careful and accurate reduction, requires, as a rule, a general anæsthetic for thorough relaxation of the muscles.

2. Local fixation splints are necessary to prevent lateral deviations at the seat of fracture. As a rule, there is a tendency to displacement in one direction greater than in any other. It is my custom after finding out this tendency in each case to apply one short apposition splint, and may be a counter splint (one on the opposite side of the limb for counter-pressure), and secure these by a bandage, then apply the immobilizing splint.

3. Immobilization may be obtained in a variety of

ways. As I said before, a permanent extension apparatus is, as a rule, not necessary in transverse fractures. I think plaster-of-Paris makes the ideal dressing for permanent fixation in treating these fractures. In using the plaster-of-Paris it should be applied only when the reduction has been accurate and complete, and great care should be exercised to be sure the bones remain in good apposition while the dressing is being applied. If the fracture is below the middle of the femur it is not necessary to fix the hip-joint, but if the fracture be above the middle it will be best to apply the dressing to the pelvis also, and thus immobilize the hip-joint. It will be sufficient, as a rule, to incorporate the short apposition splints immediately about the fracture in the plaster dressing. When plaster-of-Paris is used, a piece of veneering or tufa wood splint, cut short enough to go across the fracture and project about five inches above and below the line of fracture, makes a very neat and efficient splint. The piece of wood should be accurately moulded to the contour of the limb. I have also used strips of tin for this local fixation, and they are also excellent for the purpose. Notwithstanding care in applying this dressing, it will be well, in a week's time, to cut the plaster dressing and make an inspection of the seat of fracture. This should be done by a simple linear longitudinal incision through the dressing, and then separate the edges sufficiently to feel the fracture accurately. This inspection may be made without destroying the splint and without disturbing the fracture. If the bones have slipped or are not accurately applied, the dressing must be removed and the reduction again performed. This is regarded by many physicians as a humiliating occurrence, but it is in no sense true, as muscular spasm may sometimes undo the nicest adjustment of the fragments, and overcome the most careful and well applied immobilization. Besides it is far better to make the correction early than to wait

with the hope of gradually overcoming the deviation by readjustments later on. When a transverse fracture of the femur slips the deformity is marked, and it is very difficult of correction when once even partially united.

In very young subjects, luckily, apposition is usually easy, but immobilization is difficult. For very young children I like a frame similar to that on page 122, Fig. 25, and the limbs and pelvis (both) fixed by plaster-of Paris bandages to the frame. With this dressing the child can make no voluntary movement of the lower extremities, and it may be moved about in bed or from one bed to another with impunity.

Fractures of the femur in very old people are usually transverse or nearly so. I would advocate an immediate plaster-of-Plaster dressing for these and an early release from bed.

I must give a word of warning to physicians who are not constantly using plaster-of-Paris in surgery. After every fracture, especially after a fracture of the thigh bone in young vigorous adults, the violence necessary to produce the fracture will have inevitably also produced considerable injury to the soft tissues of the limb; there will almost surely result some swelling. Besides, plaster-of-Paris bandages shrink in drying. *Never, therefore, leave a plaster-of-Paris dressing longer than a few hours without carefully inspecting the extremity to which it is applied in order to be very sure hurtful constriction is not taking place.* In private practice this is a very important matter. I have heard of some very disastrous results from leaving freshly applied plaster splints or casts on for twelve hours without inspection. In skillful hands, accustomed to the use of the plaster, it is exceedingly efficient, and a well applied cast will prevent an excess of swelling in a fractured limb without anything but good resulting to the patient. The tyro should always use padding carefully and smoothly applied in cases where swelling is

likely to occur. Every operator should insist upon being notified in case of great pain coming on after application of a plaster-of-Paris cast, and should always warn attendants to carefully watch the fingers or toes for several hours after a plaster cast has been applied to an extremity, and in case they become much swollen or are very white or *blue the cast should be cut at once, and all constriction relieved down to the skin.* A linear longitudinal section of the cast will not vitally injure its value as a splint, and will permit separation of the edges of the cuts sufficiently to restore circulation in the constricted member.

After so-called "permanent extension" has been on an oblique fracture for three or four weeks, sufficient union will have taken place to prevent easy slipping of the fragments. When this is demonstrated to have taken place I apply a plaster-of-Paris splint, and get the patient out of bed within a week thereafter, unless the fracture is very near the upper third of the bone. In this case I keep the patient in bed for five weeks at least.

In the majority of cases in six weeks the immobilization splints may be removed in both oblique and transverse fractures. If the apposition has been good union will be as a rule pretty firm. Passive movements of the joints, bathing, and massage should now be begun, and a light Bavarian plaster splint or a light cast be applied and cut into two sections as soon as it dries. Such a splint may be moved daily and passive movement and massage be daily performed. In eight weeks union is usually strong enough to enable one to discard splints. In ten weeks the patient may begin to walk without crutches. It is extremely rare to have a result so perfect that no shortening takes place after a fracture of the shaft of the femur. Dr. Thos. G. Morton, of Philadelphia, showed years ago how fallacious the ordinary measurements of extremities are, by proving that perfectly symmetrical limbs, as to length, are practically non

existent. No appreciable limp will occur if the shortening is less than two inches, and the result may be considered good if the apparent shortening is no more than one inch.

I have heard physicians speak of *persistent callus;* in my experience *persistent callus* means *overlapping of fragments* in an oblique fracture. This beneficent

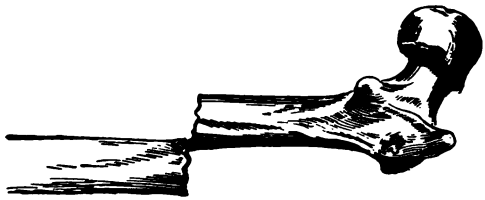

Figure 32 shows the unslightly projections produced by sliding of the ends in transverse fractures.

product of nature will persist for many months, and is only modified subsequently by the rounding off of angles and projections by the pressure of fasciæ and muscles.

I have seen one case of such enormous bony development after a fracture about the middle of the femur that I thought it was an osteo-sarcoma. This case I saw through the courtesy of the visiting staff at the Reading, Pa., Hospital some years ago. Non-union persisted for months, but I was informed afterward firm union of the bone took place, and there has been no indication of malignant character, though the excessive callus persists. Such extreme cases are very rare.

I have been fortunate enough never to have a case of ununited fracture of the femur leave my hands, except in two cases: One was a compound comminuted fracture where there was loss of more than three inches of bone. The other was a case of metastatic carcinoma of the femur; a fracture occurred at the seat of the carcinoma and, of course, failed to unite. The compound comminuted fracture case united afterwards, however. I have *seen* a number of cases of ununited fracture of the femur and I know that

the surgeon is not always to blame for these bad results.

Fracture of the Lower End of the Femur.—As noted in the statistics given in the beginning of this article on fractures of the femur, fractures of the condyles are comparatively rare. Falls, direct blows, or, as also noted by Hutchinson and Barnard in their paper on "Separation of the Epiphyses of the Femur" (*Lancet*, May 13, 1899, p. 1275, et seq.), twistings of wheels have been the causes of these fractures.

In my experience these fractures are nearly all transverse, or nearly so, when they are simple fractures.

I cannot recall a case of fracture of only one condyle. Fractures just above the condyles at or near the epiphyseal line, or a splitting through the condyles (longitudinal fractures) are the forms I have encountered.

Fractures at the Epiphyseal Junction.—These fractures are most common in children, and in these cases are separations (rather than true fractures) of the epiphysis and diaphysis. They are produced most frequently by violent over-extension, as for instance by the twisting of a wagon or carriage wheel when a child has had its leg caught between the spokes of a revolving wheel. The displacements are usually very characteristic, as shown by the diagram subjoined (see Fig. 34). The end of the upper fragment, or diaphysis, projects backward into the popliteal space and the epiphysis is tilted forward Sometimes the periosteum and fibrous tissues about the bone at this place are not ruptured, and occasionally a thin slice of bone splits off with the periosteum. The pressure of the jagged upper fragment against the vessels, which are very close upon the bone at this place, may produce a thrombus in, or mechanical closure of, the vessel, with the result of gangrene of the foot, and perhaps a part of the leg, as in the case published by Hamilton.

Injury to the femoral vessels higher up, I have just found out, by the ends of a fractured femur may also very readily occur. I have at present an Italian in the hospital, 25 years old, who apparently is a strong,

FIG. 33. Photograph showing excessive development of callus after fracture of the middle of the femur, simulating sarcoma.

healthy fellow. He was injured by having a heavy stone fall upon him in a quarry, and besides some inconsequential lacerations of the scalp and thigh, had his right femur broken about the middle of the shaft. The usual modification of Buck's extension apparatus was applied. Twelve hours afterwards the foot was found mottled, and the toes white and cold. Twenty-four hours afterwards the whole foot and the lower part of the calf were mottled and cold. There was no swelling and no mark to show any harmful constriction. Upon inquiring carefully into the matter, I found that the fellow is exceedingly emotional and hysterical; he tore off his dressing, persisted in

sitting up, and threw himself violently about the bed; even while on the table when his fracture was being reduced, he suddenly sprung up and slid the affected extremity over the side of the table. My assistant who was attending to the man, said the ends of the fragments were driven downward and inward so violently that he was afraid the vessels would be torn in two. There is undoubtedly a thrombus in the femoral artery, and the man will probably lose his foot if not his leg.

FIG. 34. Displacement and position of the fragments after epiphyseal separation of the lower end of the femur. (Taken from Mr. Hutchinson's and Mr. Barnard's article, *Lancet*. May 13th, 1899.)

These happenings suggest the importance of early and thorough reduction and a fixed immovable dressing for these cases. In reducing them general anæsthesia is necessary. An assistant should make extension in the axis of displacement, which in most cases will be a hyperextension, until the ends of the fragments are disengaged; then the operator should make firm pressure directly on the fragments

while the assistant gradually flexes the knee to an angle of about 60°. This flexion relaxes the gastrocnemius muscle which has tilted the lower fragment or epiphysis forward, and brought the articular surfaces of the condyles upward—when this muscle is relaxed it is much easier to press the fragments into place, and when once reduced they are not apt to slip apart. Hutchinson and Barnard (See London *Lancet*, May 13, 1899, p. 1275, et seq.) recommend that the extremity be put up in a flexed position. I think this is not necessary if the plaster-of-Paris bandage, which should be used, is reinforced, posteriorly, above, at and a little below the popliteal space, by a strip of tin curved to fit into the slight concavity of this space when it is relaxed. Flexion in reducing the fracture is very important, however, as the articular surfaces of the condyles are very apt to remain upward and forward unless the gastrocnemius muscle be thoroughly relaxed during the reduction.

As I said above, the plaster-of-Paris dressing is the best one, in my opinion, for these fractures. It should remain on for two weeks, then be cut and the fracture carefully examined, and if it be found in good place the same splint may be returned and kept on for two more weeks. After this the splint should be removed and careful passive movements made at the knee, and a light plaster dressing again applied for ten days, when it may again be removed, and, as a rule, left off. The limb after this should have daily graduated massage and passive movements and be bandaged with a flannel bandage. The patient should not be allowed to walk on the limb for eight weeks, as the pressure of his weight and the obliquity of the articular surfaces are apt to cause some deviation and much aching pain afterwards.

Fracture of the Condyles.—As I said, in my experience fracture of only one condyle is rare. I have most frequently seen inter-condyloid or almost longi-

tudinal fractures—very commonly these fractures are multiple, that is to say a sort of T fracture. In these cases the condyles are much broadened, and sometimes the lower end of the upper fragment projects backward into the popliteal space.

FIG. 35. Intercondyloid fracture of the femur.

The reduction and after-treatment of these fractures should be similar to that for epiphyseal fractures. The prognosis as to function of the knee-joint is, however, not so good. After a month in splints of plaster-of-Paris, careful graduated passive movements and massage will do a great deal towards restoring the functions of the joint, but it is rare to obtain absolutely free movements after these injuries. Patients should be warned of this at the beginning of treatment. As the attachments of the crucial ligaments are usually broken in these fractures, the knee-joint will likely never be as strong as before, and patients will be apt to suffer from sudden wrenches and giving-way of the knee. Some firm apparatus about the knee should be worn for months after these injuries to protect the joint.

Rheumatic and gouty subjects are very apt to have pain about the affected knee-joints for long periods after fractures of the condyles. Anti-lithic treatment should be employed from the beginning of the treatment of the fracture, and be continued for at least three months.

FRACTURES OF THE PATELLA.

A review of the cases of fractures of the bones of the lower limbs, which I myself have personally seen and treated in the last few years, would seem to indicate that fractures of the patella in rural communities and amongst mill, mine, and railroad employees are relatively rare.

I have had 122 fractures of the femur of various kinds, 242 fractures of the bones of the leg of various kinds, and only 15 fractures of the patella. In urban districts, I am of the impression, fractures of the patella are far more frequent. I have not the data and can therefore not draw the absolute inference, but from the experience of city surgeons and the records of city hospitals it would appear that men who live in the country and those employed in heavy and dangerous work of steel factories, mines, and in railroads are much more apt to have the femur or the leg bones broken; the city dwellers, who, as a rule, have lighter work and are exposed to slighter injuries, suffer much more frequently from fractures of the patella.

Of the 15 fractures of the patella I have treated 11 were noted as simple fractures, 1 was comminuted, 1 compound and comminuted, and two cases had fractures of both patellas. The text-books note that muscular spasm or strong muscular action is the commonest cause of fracture of the patella. In my own experience I have found direct violence almost equally as frequent in producing fracture of the patella as muscular action. Direct blows or falling on the bended knees have produced about one-half of the cases I have treated. This may account for the fact that I have had but few cases which showed remarkable separation of the fragments, and it may also explain the fact that I have had occasion to operate for fixing the fragments in position only three or four times. I have been fortunate enough to have good

functional results in every case, and in several cases I believe bony union has taken place.

It seems to me there has been some very unfortunate teaching during the last fifteen years with reference to the treatment of fractured patella. Leaving out of consideration the enthusiastic monographs which followed the early brilliant successes of aseptic operators, because these may be ascribed to the confidence born of the new assurance gained from the surety of early modern technique, I must however protest against such dogmatic statements as the following, which I read only recently in a journal fresh from the printer's hands.

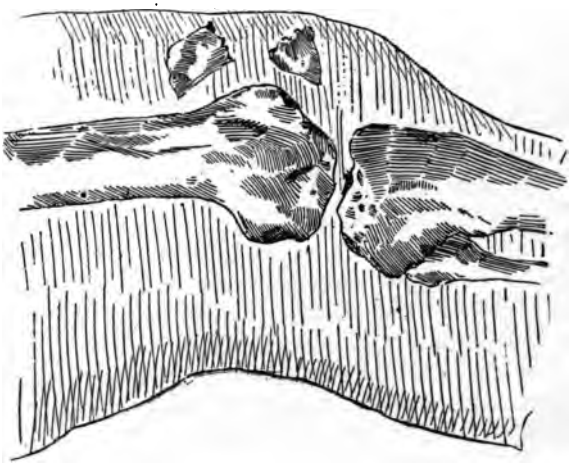

FIG. 36. Fracture of the patella, sketched from a radiograph.

1. "The results of the non-operative treatment are unsatisfactory, both as to long confinement and functional disability.

2. The methods of maintaining apposition of the fragments by external appliances are unsatisfactory and unscientific. * * * *

4. The operative method saves months of confinement, and gives permanent results."

It would of course be presumptious for me, with the limited experience I have had in treating fractures of the patella, to attempt to controvert the opinions and the most dogmatic conclusions noted above by my own *ipse dixit.* Fortunately there is a most conclusive monograph based upon the largest collection of cases in the English literature backed by the opinions of many of the best surgeons of the world upon this very subject. I refer to a paper read by Dr. Chas. A. Powers, of Denver, Colorado, at the 1898 meeting of the American Surgical Association and published in the transactions of the "American Surgical Association Vol. XVI. p. 53, *et seq.*" This paper was based upon the study of 786 collected cases of operation for simple fracture of the patella. Of these cases 733 made satisfactory recoveries, 39 resulted in marked stiffness or ankylosis, 13 *died,* and one required amputation.

Besides these cases, Dr. Powers collected the personal opinions of the members of the American Surgical Association, the members of the New York Surgical Society, and of the members of the Philadelphia Academy of Surgery. After quoting these opinions Dr. Powers writes as follows: "As one reads the personal opinions cited in the foregoing pages he is struck by the number who emphasize the fact that only surgeons of, if I may use the term, exceptional judgment and skill, working amid the most perfectly controlled surroundings, equipped with all that goes to make complete asepsis, and with carefully trained assistants, should undertake this operation. It is one which entails exceptional responsibility on the operator."

It is a well-known fact that surgeons do not as a rule like to report their failures. The foregoing statistics and opinions represent the work of the most careful, skillful, and best prepared surgeons in the world, and yet nearly 2 per ct. *of the cases died after operation,* and these surgeons recomend the operation

only in selected cases and with the best surroundings, and by the most practiced hands. What the results have been in the hundreds of cases not reported we can only conjecture. I personally knew of a case operated on by a skillful surgeon and a first rate aseptician which required an amputation afterward, high up in the thigh, on account of sepsis. Dr. Powers mentions another case of which he knows.

All this proves the ordinary operation for fixing the fragments after a simple fracture of the patella is always attended with risk, both to limb and life. The percentage of satisfactory recoveries is certainly high, but I think in careful and skillful hands the mechanical treatment is in the majority of cases equally good, and is devoid of risk. Unquestionably some cases demand operation. While I wish to sound a note of warning to the enthusiastic young operators who have treated two or three cases by the open operation method with good results and forthwith rush into print stating that the purely mechanical methods are obsolete, unscientific, and unreliable, I freely admit that the operative method has its place, and that it has been proven to be efficient; nevertheless it should *not* be employed as the rule, and it should be used only in selected cases, and by men who have the very best technique.

The treatment of fractures of the patella should therefore be considered under two heads. 1. The mechanical treatment. 2. Operative treatment.

One should especially individualize every case of fracture of the patella. The method of treatment to be employed must depend upon: (1) the degree of separation of the fragments and the condition of the fragments themselves, *i. e.*, whether they are comminuted or tilted; (2) the degree of effusion into the joint and synovial sac; (3) the degree of injury to the soft tissues about the bone and joint; (4) complications, viz., the presence of injuries to other parts of the body and their severity.

The separation of the fragments is as a rule greater in cases produced by pure muscular contraction than those produced by direct violence. The greatest separation I have seen has been about six centimeters (about two inches and a quarter.) When this degree of separation exists or when the separation is considerable the lower fragment is apt to be tilted forward. In such cases purely mechanical means will not, as a rule, result in obtaining good apposition. This is especially true when there is great effusion present. These cases are proper ones for the open operation methods.

If the soft tissues are much contused and swollen, together with great effusion into the capsule of the joint, tentative treatment had best be employed for a few days. That is to say, elastic bandages (flannel or stockinet) applied firmly but not too tightly, elevation of the foot, and a posterior splint should be used. I do not think ice applications on badly contused tissues in cases of fractured patella are very efficient, and I must confess I am a little afraid of them because of the benumbing effect, and the vasomotor overstimulation is apt to devitalize the injured tissues. Moderate pressure and complete rest of the extremity seems to be the desideratum. The swelling will be reduced sufficiently in a few days and the bloodvessels resume their tonicity; then either an operation should be employed if the fragments cannot easily be coapted and retained, or some mechanical contrivance be applied. It is the judgment of some of the best surgeons that in cases of severe injuries to the soft tissues an operation should not be employed, as the injured tissues do not heal readily. I am rather of a contrary opinion, as I think the drainage of effused blood and serum obtained by the necessary incision relieves the pressure, and, if the operation be thoroughly aseptic, rather assists the recovery of the tissues. The operations I have done

have been in just such cases and have resulted very happily.

Serious injuries of other parts may greatly modify the indications for operation. I am decidedly opposed to the open method of treatment in cases which are greatly reduced by loss of blood or by serious crushes of some other member. In such cases an added wound does great harm, and the condition greatly increases the risk of the operation. I think therefore that serious complications generally make mechanical treatment imperative. I am aware, however, that this is contrary to the opinion and advice of many other surgeons.

Of course a compound fracture of the patella is an invitation at once for suturing the fragments.

To sum up—it seems to me that the indications for employing mechanical treatment are in any case of simple fracture, effusion and swelling not excessive, fragments only separated to a moderate degree and not tilted badly, fragments movable and coaptable under relaxation of muscles, old age of the patient, serious complicating injuries, and especially conditions and surroundings which will not admit of thorough asepsis.

Mechanical Treatment of Fracture of the Patella. —The patient will sometimes require a general anæsthetic when there is persistent spasm of the quadriceps muscle, in order to obtain coaptation of fragments. An assistant should elevate the foot, and the leg should be fully extended, *but not over extended.* The operator should grasp the fragments with either hand, and while steadying the lower fragment and bringing it flat down, if it be tilted, he gradually draws the upper fragment down towards the lower. If he finds he can do this and if he decides to use the simple posterior splint with adhesive straps and bandage (see Fig. 37), this should now be applied, and the foot-piece with the patient's foot in its proper position in it, rested on an elevator. The operator now brings the upper frag-

ment down to the lower, and *firmly rubs the fragments together* in order to rid the freshened surfaces of shreds of synovial membrane, torn capsular or muscular fibres, and while he firmly holds the fragments in apposition the assistant should place a compress made of a piece of blanket folded two or three times, about five centimeters wide and long enough to reach over the anterior surface of the thigh, and strap this firmly

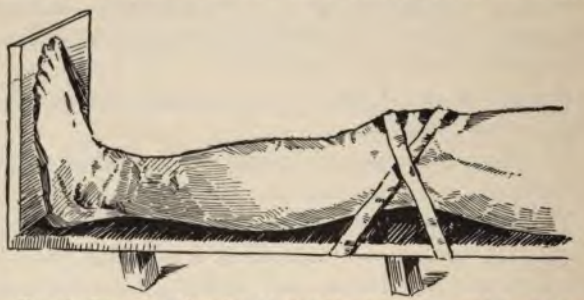

FIG. 37. Diagram showing a simple posterior splint with foot-piece and cross-bars to prevent lateral movement. The foot is raised and the fragments of the patella held together by adhesive strips over compresses. Over this a firm bandage of flannel should be applied.

downwards by passing a strip of adhesive plaster, not so wide as the compress, across it and obliquely downwards and backwards over the splint, to which it is fastened. Another compress and adhesive strip should now be fixed below in a like manner. These strips should be just above the upper fragment and just below the lower fragment. The effect of these compresses, so held, is apt to be a slight tilting upward of the fractured surfaces. To obviate this I am accustomed, when using this dressing, to cover over the patella with a thin compress and continue the series of adhesive strips by overlapping straps right down over the whole patella. These should follow the course of the first strips and be laid on obliquely. After this the flannel bandage is applied and the patient's foot kept elevated. While I have found the foregoing an efficient dressing in some cases I very much prefer, if the case will permit it, a plaster-of-Paris dressing.

The method is similar to the foregoing except that the posterior splint is not applied and, as a rule, only the two first strips of adhesive plaster are used. These strips must be obliquely placed and not reach entirely around the limb, in order to avoid constriction. After this the flannel roller is applied firmly and then the plaster-of-Paris roller. After the dressing is dry the limb may be elevated for about one week, by means of the crossbar over the bed, and suspension, as indicated in Fig. 38. After the limb has been suspended or elevated for a week, it may be lowered to a

FIG. 38. Showing double inclined position and suspension. In this case extension and suspension were obtained by bandages placed under the permanent dressing.

level, as the muscle will have lost its irritability, and will not be apt to resist a little stretching. In two weeks I usually get the patient out of bed, and allow him to go about on crutches a few days after he has been out. In three weeks the dressing should be cut and the patella inspected. Usually, if all has gone well, I

take off the whole dressing, bathe the limb in alcohol, and have the muscles and knee-joint massaged, then reapply the same dressing. After four weeks daily massage and passive movements, very gently and gradually begun, are employed, and the patient encouraged to walk about with crutches with a light splint of leather, felt, or plaster-of-Paris. I think the first material is best after four weeks. After six weeks the splint may, as a rule, be removed, and only a flannel bandage be worn. The patient should be instructed to use the limb gradually, continuing with crutches for another week, and do gentle voluntary flexion and extension of the knee-joint many times a day. Full flexion should be possible in eight weeks.

Operative Treatment of Fractures of the Patella.—While Malgaigne's hooks or some other form of transcutaneous operative procedure are still used and occasionally recommended by surgeons, the "open method" is usually meant when operative measures are recommended, or employed, for fractures of the patella. Any transcutaneous mechanism for fixing the fragments is about as dangerous as an open operation under good aseptic conditions, and I think, except in very exceptional cases, the open methods alone should be used when an operation for fixation is required.

The indications for employing operative methods of fixation are: 1. Conditions and surroundings permitting of thorough asepsis, and a competent surgeon thoroughly practised in aseptic technique. 2. Wide separation of the fragments with persistent spasm of the quadriceps femoris muscle, and great effusion into the capsule of the knee-joint. 3. Severe contusion and laceration of the soft tissues about the patella. 4. Compound fractures. The incision must of course be made after the most thorough and painstaking cleansing and disinfection of the affected knee and neighboring parts of the extremity, as well as of all instruments, dressings and the hands of the opera-

tor and assistants, has been done. The form of the incision and its direction with reference to the long axis of the limb, I think ought to be determined by the nature of the case. When there is a comminution of the bone, or extensive laceration of the capsule with very great effusion, the transverse incision will probably be best, as this gives freer access to the joint and sides of the synovial sac, and provides for drainage if necessary; in cases of wide separation and tilting, without much effusion into the joint, the longitudinal incision will suffice. In cases having considerable laceration of the skin and subcutaneous tissues the incision should be so placed, if possible, as to include the lacerations, so that the skin lesions shall not be multiplied unnecessarily.

Whichever incision may be selected it should be made with one stroke of the knife directly through the skin and subcutaneous connective tissues, not by a number of successive strokes by light dissection, as this will permit retraction of the layers and prevent accurate apposition and fitting in suturing afterward.

As little lateral dissection as possible should be done, and the fingers should not as a rule be introduced into the deep parts of the wound, if this can be avoided, as this increases the danger of infection. The manipulations should be accomplished by pressure from the outside in restoring the fragments to their proper positions, and the necessary removal of clots, shreds etc., should be done by irrigating with a hot sterile normal saline solution and by forceps and scissors. It is very important to remove all clots and shreds of tissue from the synovial sac and joint, and carefully to free the fractured surfaces of all shreds. The suturing of the fragments may be accomplished in several ways. Silver wire sutures were used in most of the early operations, but lately some absorbable animal sutures seems to have the preference and indorsement of the best operators. I myself have used both kinds. In the first case I operated on

I used silver wire sutures passed through drill holes in the fragments, and then twisted so as to bring the fragments into close apposition; the ends left long were brought through a small incision made through the skin for this purpose at a convenient place. Afterwards these wires were untwisted and removed. In the second case I also used silver wire, but cut it short and forced the knot or loop, which marked the junction of the strands, down flat upon the bones and left it within the wound, and it remained permanently in the bone. After this I used catgut prepared by baking (size No. 2 of the ordinary scale), and in a fourth case I used chromicized catgut sutures.

In the two cases in which silver wire was used as sutures for the fragments, though the wound healed kindly, there was considerable pain and stiffness of the joint, and the patients, as long as they remained under observation, never regained flexion to ninety degrees. The catgut cases resulted in equally good union and the function and motions of the joints were much better afterward.

As to the manner of passing the fixation sutures, *i. e.*, whether through the bony fragments themselves by means of drill holes, or by passing them through the fibrous tissue about the fragments, or through the tendons above and below the fragments, I think must depend upon the individual case under treatment. If there be considerable spasm or persistent retraction of the quadriceps muscle it will probably be best to pass the sutures through the bones themselves; if the muscular contraction is not persistent, and especially if there be more than two fragments, suturing through the fibrous investments will be best if practicable.

After a very careful aseptic dressing, the limb should be encased in plaster-of-Paris, and for a week it should be suspended as indicated in Fig. 38, page 149. After this it will be best for the patient to re-

main in bed for another week, using suspension or the horizontal position for the limb, as most comfortable. A change from one position to the other is usually very grateful. At the end of two weeks the plaster dressing should be cut, and the wound and condition of the fragments inspected and ascertained. If all has gone well, the wound should be at this stage completely healed. A light fresh dressing to prevent friction may then be applied, and the same plaster cast be fastened together by adhesive strips and a roller bandage, and be allowed to remain on for another period of two weeks. During the last period, however, the patient may be allowed to be out of bed, and may use crutches, and a high heel and a thick sole shoe on the foot of the uninjured extremity, so that the injured one may clear the ground without discomfort while the patient walks about on crutches. This also prevents the use of the flexor muscles of the thigh, which the patient will almost surely use to prevent the foot of the injured side resting on the ground. After a month has expired the first fixation splint should be removed, the leg and knee should be washed and massaged, and a light splint of felt or leather be placed along the posterior aspect of the leg, knee, and lower thigh, and bandaged on by a flannel or stockinet bandage. Better than this, however, would be a light apparatus consisting of thin, narrow, lateral steel plates riveted so as to form a joint opposite the knee-joint and ankle-joint, and with slots to prevent motion if desired, these plates to be attached to the sole of the hoe below and to a band which should encircle the mid-thigh above. (See Figure 39.) With such an apparatus the patient is relieved of the feeling of weakness and helplessness in the injured extremity, and the slot or regulating screw arrangement permits of as much or as little flexion as may be desired, and only when desired. Persistent voluntary and passive movement should be employed daily from six weeks after the

fracture, if the union is good, until the functions of the extremity are fully restored. Light gymnastic apparatus to strengthen and recuperate the flexors may be necessary in cases which have required fixation apparatus for an extraordinary length of time. Massage is especially useful in regaining the motions and dispelling swellings about the joint. The fortitude of the patient must in many instances be stimula'ed by convincing him of the absolute necessity for persistent movements, for the exercise of the joint is at first exceedingly painful.

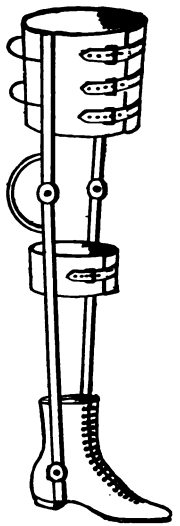

FIG. 39. Long leg brace which may be used for supporting the extremity when a patient begins to be again active after fracture of the patella.

FRACTURES OF THE BONES OF THE LEG.

In a hospital service which has included a large number of fractures, I find in reviewing the cases for the last few years, that fractures of the bones of the leg have been more numerous than fractures of any other bones.

Of 232 fractures of the bones of the leg, 41 were simple fractures of the tibia, 53 were simple fractures of both bones of the leg, 24 were simple fractures of the fibula, 14 were Pott's fracture of the fibula, 17 were compound fractures of the tibia, 7 were compound fractures of the fibula, 71 were compound fractures of both bones, 2 were simple fractures of both bones of both legs, and 3 were compound fractures of both bones of both legs.

Fractures of the bones of the leg are rare in children. As a rule, when a child's tibia seems to be broken it will be found, unless some direct violence has caused the fracture, that the case is one of separa-

tion of the epiphysis, usually the upper epiphysis. Fractures a little below the middle of the shaft are most common in the tibia in adults, and when the fibula is also broken, the bone usually gives way a little higher up than the tibia.

FRACTURES OF THE TIBIA.

Practically, in discussing the treatment of fractures of the tibia, it is best to make two divisions only, and not with reference to the locality of the fracture so much as with reference to the nature of the fracture itself. Fractures of the tibia may, therefore, be classed as 1, Transverse fractures; 2, Oblique fractures. As a matter of fact, most of the fractures of the upper part of the tibia are transverse fractures. Occasionally one meets with the rare exception of a very oblique or almost longitudinal fracture, which runs through the head and involves the articular surfaces of the bone. These fractures, as a rule, unless they are badly comminuted, result in very little displacement or separation of the fragments.

1. *Transverse Fractures of the Tibia.*—As was said above, transverse fractures occur especially about the head of the tibia, though one now and then finds them lower down in the shaft. These fractures are very difficult to reduce, and without a general anæsthetic, unless it be *immediately after the fracture*, it should not, as a rule, be attempted. Give an anæsthetic, and when the patient is thoroughly relaxed, reduce the overlapping fragments by gentle but firm manipulations. As a rule, extension will be of little service, bending downward or to either side at the seat of fracture, as the case requires, is usually the motion necessary from an assistant's hands, while the operator presses directly on the fragment near but *not immediately over the ends of the fragments*, as this may cause the sharp upper edges of the jagged bone to puncture the skin. The displacement, as a rule, is antero-posterior, sometimes, but rarely lateral.

The upper fragment projects forward and the lower one backward, so manipulation will consist chiefly

FIG. 40. A, upper fragment; B, lower fragment.

in raising the lower fragment while holding the upper one firmly in place, while the assistant, by grasping the foot, bends the lower fragment upward or downward or from side to side, as may be necessary. The assistant must be instructed not to make these movements so energetically as to fracture the fibula, as this bone will serve, after reduction, as a stay for the fracture, and help to prevent displacements.

When thoroughly reduced there is very little tendency to displacement if the extremity be kept quiet. Almost any simple well-fitting splint, which stiffens the leg, will serve, but in my opinion plaster-of-Paris is the splint material for these fractures, and indeed, it makes as nearly as possible the ideal material for nearly all simple fractures of the leg. The so-called Bavarian plaster-of-Paris splint may be used to advantage in transverse fractures.

In handling cases of transverse fracture it is of importance to reduce the fracture as soon as possible, and carefully, to avoid making additional pressure on the skin over the displaced bones, as the skin is in nearly every case greatly stretched and frequently injured by the projecting fragment, and any extra pressure, or the pressure of the displaced fragment long continued, is apt to be followed by sloughing of the skin, when a compound fracture will result, and, very likely, suppuration. After a transverse fracture has been thoroughly reduced and the fragments accurately adjusted, as I said before, there is comparatively little danger of the fragments slipping, if the foot be kept quiet and some stiffening splint be applied to the leg. Plaster-of-Paris splints I have found ideal in these cases. Two strips of tin, one on either

side, or some flexible wood splints may be used as apposition splints at the seat of fracture, to prevent any movement of the fragments, until the plaster hardens. Before applying the plaster it will be well to pad the leg with an even layer of cotton wool and to use a flannel bandage over the cotton, neatly, but not too tightly, applied, from the toes to the knee. If the fracture be near the knee it will be well to extend the plaster dressing six inches above the knee. More or less swelling will surely result after fractures of the bones of the legs; it is well, therefore, to bear this in mind, and never use very tight bandages. The cotton wool when properly used, and the bandage skillfully applied, will prevent any hurtful pressure resulting, but the surgeon should carefully watch the extremity for twelve hours after applying the dressing, and he should instruct the patient and his attendants to notify him at once in case great pain in the extremity or swelling and discoloration of the toes should take place. In any case which it will be impracticable for the surgeon to see within ten hours after the application of the plaster-of-Paris dressing, he should insert, while applying the dressing, a narrow strip of tin under the plaster just over the flannel bandage, and instruct the attendants, in case swelling, and persistent and very severe pain should follow, at once to cut through the bandage upon the tin strips with a penknife, and so loosen the dressing. The cutting will not materially impair the usefulness of the dressing. It may afterwards be held together by adhesive strips or by a roller bandage.

Oblique Fractures of the Tibia.—These fractures occur usually in the middle two-thirds of the tibia; the obliquity may be antero-posterior or lateral. The displacement is usually marked, and the overlapping is considerable. In cases where the fracture makes decided "shoulders" at the periphery of the bone, as in the diagram, after reduction, the fragments may remain in place and a fixed dressing may be

applied at once after reduction. When, however, there is a bevelled obliquity, especially when the obliquity is acute, it is very difficult to retain the fragments in place. As a rule, oblique fractures may be reduced without an anæsthetic, but the operation is exceedingly painful; on this account, if the condition of the patient will permit it, an anæsthetic had best be employed. This also assures much greater facility in the necessary manipulation and the application of apparatus. An assistant

FIG. 41.

should grasp the foot firmly by the heel and ball of the foot, and make steady extension, at first in the axis of displacement, when the fragments are somewhat disengaged, in the normal axis of the limb, while the surgeon in charge manipulates the fragments at the seat of fracture. When the fragments are brought into the position necessary, the operator should firmly press them together, and request the assistant to continue his extension, and to make the fragments jam as much as possible by using the foot as a lever to raise, lower, or turn it one side or the other as may be necessary to make the oblique surfaces press hard against one another.

FIG. 42.

While the assistant continues his extension and "jamming," the fixation dressing should be applied. At this stage anæsthesia is a great help, without it it is almost impracticable to retain good apposition in very oblique fractures. I have tried many varieties of splints and dressings for these fractures, and I must confess I have frequently failed with the greatest care and attention I could give the case to secure

union without some overlapping, and, of course, some deformity. In the majority of cases plaster-of-Paris will be the best dressing for the fracture, and I almost always use it. When there has been much contusion or abrasion of the skin I have used temporarily wooden lateral splints, shown in the photograph, Fig. 43, for a few days, until the swelling was relieved or the abrasions healed, and then applied the plaster dressing.

FIG. 43. Wooden lateral splints for fractures of the bones of the leg.

A good deal of experience in treating compound fractures of the bones of the leg has taught me the almost absolute safety of using some mechanical fixation at the seat of fracture if careful asepsis be maintained. The great difficulty of applying any splint or dressing which will retain very oblique fractures of the tibia in good apposition, and some very excellent results with local fixation, have led me to believe that the best treatment for these oblique fractures, *espe-*

cially those having lateral displacements, when the surroundings of the patient will make one reasonably sure of asepsis, is to cut down upon the fragments, free them of all shreds of lacerated tissue, wash out with a sterile normal salt solution all blood clots and detritus, bring the fragments into accurate apposition and hold them by nails, ivory pegs, or by what I ordinarily use, viz., a nickel plated steel plate across the fracture held in place by ivory pegs (see photograph Fig. 44). After firmly fixing the fragments together close the incision, apply a sterile dressing, and over all plaster-of-Paris bandages. This dressing should remain on for about three weeks if all goes well, then be cut, the fracture carefully examined, and if in good position and union fairly begun, the plate or nails may be removed and another plaster bandage applied. This last bandage should remain on for two weeks longer, and then the extremity be managed as usual. Dr. John B. Roberts has recommended sub or transcutaneous nailing in oblique fractures. The nail punctures make the danger of infection about as great as it is when an incision is used, and I think it is a great advantage to be able to remove the shreds of muscle, blood clots,

Fig. 44. Nickel plated steel plate with ivory pegs to hold it in place.

etc., from the ends of the fragments, and be sure by actual sight that the fragments are accurately fitted together before applying the nails or plate. I am aware that these recommendations will strike many physicians as radical, but I firmly believe they are

proper and right, and the very best treatment when one can have proper surroundings and appliances. No one should attempt these operations who is not familiar with thorough aseptic technique, however.

Next to the open method with local fixation, I believe the best treatment for these very oblique lateral displaced fractures, below the middle of the tibia, is an old-fashioned fracture box with movable sides. With this fracture box, by elastic extension from the malleoli and heel by means of adhesive strips and rubber tubing, and by varying the padding in the box, especially by the facility of examining and watching the fragments, one may keep the overlapping from becoming obtrusive and excessive. This method of treatment is very irksome and trying to the patient, however.

Plaster dressing, whether applied for transverse or oblique fractures of the tibia, should be cut and the fracture carefully examined in two weeks after it has been applied, if it has proved comfortable. If it has caused persistent pain, or if pain persists, no plaster dressing should be allowed to remain without cutting and examination of the seat of fracture in the course of forty-eight hours. If the coaptation has continued good the ends of the fragments will have begun to unite, and a fresh and firmer plaster dressing may be applied in case the subsidence of swelling has made the first one loose. I think it much better to apply a fresh cast, as a rule, than attempt to make the first one fit snugly by cutting out a section or by padding it more. Either of these expedients is apt to result in irregularity somewhere within the cast, and irregular pressure will cause pain and swelling, and hinder rapid union, as well as make the patient very uncomfortable. There is usually very little inclination to displacement at this time if the limb be carefully handled. An alcohol rub of the skin at this time will be very grateful to the patient and promote the circulation in the skin.

If the fragments have slipped out of place they should be restored by the proper manipulations (usually the same as were necessary at the first setting), and a fresh dressing applied. The necessity for this is very humiliating to the surgeon, but it is far better to face the obloquy and meet the emergency at this period when the accident may be repaired than to allow very faulty apposition to unite firmly, and permanent distortion to result afterwards.

The second cast should remain on for two or three weeks if all goes well. After the second cast has become firm and proves comfortable the patient, as a rule (especially after transverse fractures), may be allowed to be out of bed, and in a day or two be allowed to go about on crutches. In the using of crutches in these cases I wish to emphasize the importance and value of the patient wearing a raised shoe (high heel and thickened sole) on the un-

FIG. 45. Skiagraph showing an oblique fracture of the tibia partly united. The fragments have slipped out of proper position.

injured extremity, so that his injured extremity may be quite clear of the floor when he walks. This will obviate the necessity of flexing the leg at the knee or swinging it forward by flexing the thigh. Both of these positions are tiresome and the muscular action required is apt to displace the fragments.

After five weeks, as a rule, the cast or splints may be discarded; the extremity should be massaged daily, rubbed thoroughly with alcohol and bandaged with a flannel or stockinet bandage. Walking may now be tentatively begun with the assistance of crutches, at first only a little weight put on the injured extremity. Daily passive movement of the ankle-joint and toes, and gradually increasing active movement at these joints should be enjoined. After six weeks, in favorable cases, the patient may discard the crutches for a cane. After this a gradual return to activity may be allowed.

The so-called *ambulant* treatment is permissible for transverse fractures and for oblique fractures which have decided shoulders: in my judgment, it should never be allowed for very oblique bevelled fractures. This method consists in the use of a snugly fitting plaster dressing, applied by first padding the sole of the foot on the injured side, an inch and-a-half or two inches thick, so as to raise the foot from the lower layer of plaster, and when the dressing is hardening to carefully mould it about the tuberosity and prominences about the head of the tibia. The dressing must be thick and very firm. In this way the pressure is transfered from the sole through the dressing to the region just below the knee. As soon as the plaster has thoroughly dried the patient may be allowed to go about with a crutch or cane, and may bear weight on his affected extremity. For selected cases of transverse fractures this method is safe, and very gratifying to business men for whom it is very important to be able to go daily to their offices or counting houses.

FRACTURES OF THE FIBULA.

Uncomplicated fractures of the fibula are due almost always to direct violence. My statistics show that such fractures are not uncommon. A fracture of the fibula is very commonly an accompaniment of tibial fractures, and Pott's fract-

ures of the fibula are not rare. These last fractures are produced commonly by indirect violence. In the former case, however, the tibial fracture is the fracture for treatment, as a rule, and in the latter the fracture of the fibula I regard as secondary to the tearing off of the point of the internal malleolus and internal dislocation of the astragalus. In other words, the fracture of the fibula in these cases is but a secondary complication of the chief injury, and should be so regarded in the treatment. I purpose to consider this matter more particularly under a separate head when I come to write about the treatment of fractures of both bones of the leg, and of Pott's fractures.

Of 232 fractures of the bones of the leg 31 were fractures of the fibula alone; 24 were simple fractures of the fibula, and 7 were compound fractures of the fibula.

As a rule, the displacement in simple fractures of the fibula is very slight. There is usually a little lateral overlapping. The tibia acts as a most efficient stay for the fractured small bone, and usually prevents any serious movement of the ends of the fracture. There is usually, however, the traumatism produced by the direct fracturing force to deal with. This may be severe sometimes, and it is this which must be chiefly considered in managing fractures of the fibula. Severe contusions and lacerations must receive the treatment proper for each individual case. With thorough asepsis and rest these complicating wounds heal readily, and almost any simple steadying apparatus, which makes no uneven or severe pressure, will serve, with the aid of the unbroken tibia, to hold the ends of the fracture quiet.

Reduction should be attempted by manipulation. Usually local manipulation will suffice to bring the ends into fairly good apposition. Inward rotation or adduction of the foot will sometimes assist when the lower fragment is displaced inwards. As a rule,

perfect apposition is not obtained and is not necessary. Ensheathing callus readily forms and deformity rarely results, while the usefulness of the limb is assured by an uninjured tibia. In case the injury to the soft tissues will permit, I think a plaster-of-Paris cast makes the best splint for fractures of the fibula. This may be applied immediately and without the use of an anæsthetic. The cast should remain on for two weeks and may then be removed, if all has gone well, and a simple flannel roller bandage applied. Daily massage will assist recovery

FIG. 46. Diagram after Tillaux showing the tibio-tarsal joint and the ordinary location of the fractures in a case of Pott's fracture (Hamilton).

after this, and the patient may be allowed to walk about with the assistance of a crutch. He should be cautioned to beware of very slippery floors and uneven roads, as sudden twisting of the foot of the injured member from a fall, or stepping into a hollow in the pavement or ground, may loosen the newly formed callus. Four weeks usually suffice to restore

the usefulness of the member after uncomplicated simple fractures of the fibula. After the plaster cast has set it is not necessary for the patient to remain longer in bed. I usually allow the patient to be up and about with crutches the second day after the plaster cast has been applied.

Pott's Fractures of the Fibula.—This injury is far more than a fracture of the fibula. Indeed the fracture of the fibula should be regarded as only a secondary feature of the condition. It is really a displacement of the tibio-astragaloid articulation and

FIG. 47. Diagram showing the displacement in Pott's fracture (Hamilton).

separation of the lower ends of the leg bones, with fracture of the fibula and frequently a tearing off of the end of the internal malleolus. The displacements are the chief features requiring restitution and care.

Pronounced cases of Pott's fracture should have general anæsthesia when reduction is done. The procedure requires, else, a great deal of force and

causes intense and rather prolonged pain. Besides, when there is a tilting or semirotation of the separated fragment of the internal malleolus the complete relaxation of general anæsthesia is necessary to restore the fragment to its place. There is nearly always violent spasm of the peronei muscles and the muscles of the calf, the tendons back of the internal malleolus are violently stretched, the posterior tibial tendon may be displaced forward, and even with anæsthesia may

FIG. 48. Skiagraph of Pott's fracture of the leg, showing usual displacement.

act as an absolute bar to the replacement of the fragment of the internal malleolus. I would advise, therefore, to anæsthetize the patient unless some systemic or cardiac contraindication exist, then flex the leg on the thigh to completely relax the muscles, have an assistant support the thigh and flexed knee-joint, grasp the foot by the heel and ball, draw firmly on the foot while flexing it gradually, using at the same time gentle rocking or twisting motions from side to side, lastly invert or adduct the foot; and now while holding it by the heel with one hand attempt with the other to press the end of the internal malleolus into place. Care must be used in this manipulation not to press too hard or long upon one spot of the

tensely stretched skin over the internal malleolus, as sloughing may result. If the internal malleolus persistently remains out of place, notwithstanding careful manipulations for a reasonable time, say fifteen or twenty minutes, I think it would be best under careful asepsis, to incise down to the bone and with a blunt retractor draw backward the ruptured capsule, ligaments, and especially the tendon of the tibialis posticus muscle, and push the fragment into its place. Even if it is necessary to make a free opening into the joint on the internal surface in order to assure thorough replacement, I would do this rather than permit the unsightly displacement to become permanent, or require an operation later on to correct it. Some of these cases are extremely difficult, and nothing short of the open method, viz: free incision, will permit thorough and accurate reposition.

After the displacement has been properly reduced, simple fixation is all that is necessary. There is very little danger of the deformity recurring. I do not think Dupuytren's splint (see Fig 49) nor any other permanent inverting apparatus is necessary or proper. The wooden lateral splints, shown on page 159, Fig. 43 will serve. Far more comfortable and efficient, however, is a plaster-of-Paris cast or splint carefully applied. This should be well padded about the malleoli. This dressing may be worn for three weeks; then it should be removed, the joint be carefully inspected, the skin be bathed with alcohol, and gentle massage employed. The same splint, if cut carefully, may be reapplied and held in place by a roller bandage or adhesive strips, and be worn for another week. The splint after this may be removed, the limb again be bathed with alcohol and massaged, and only a flannel roller bandage be applied. Daily massage for a week or two weeks longer should be used, and very gradual use of the extremity with the assistance of crutches be permitted.

The first week after the injury, when a plaster-of-Paris splint is used, the patient had best be kept in

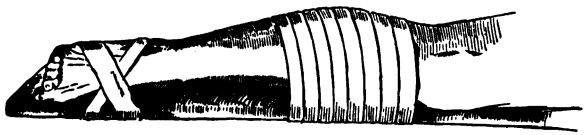

FIG. 49. Dupuytren's splint.

bed in order to keep the muscles of the extremity quiet. After this, however, the patient may be allowed to be up and about on crutches. This is the great advantage of the plaster dressing over all others, namely, it permits the patient to be up and about. A business man, if he is blessed with a fair supply of discretion, may be allowed to go to his office, if his work and situation will permit him to sit and have support for his injured member during the day, after the second week of treatment.

Fractures of the Malleoli.—Not uncommonly the internal malleolus is broken without any displacement of the ankle-joint, and very little separation of the fragments. This fracture requires simple rest and moderate fixation and pressure. I prefer to treat this fracture as I would a bad sprain at the ankle-joint, viz., by snug strapping with adhesive plaster. The layers are begun at the ball of the foot and are carried upward, each succeeding strip overlapping the last one slightly, just as in the strapping formerly employed for an old leg ulcer. They should be laid on obliquely and extend up to the lower third of the leg. A leather splint moulded to fit accurately and held in place by laces will also answer, or if nothing better can be had, an old stout laced shoe, the heel and sole removed to the insole, and the foot part cut off across the instep, will serve. If the patient is content to remain quietly in bed, no dressing at all is necessary, except an elastic sotckinet or flannel bandage laid on snugly, but not tightly, and the foot supported on a pillow.

Sometimes, however, by a violent inversion or eversion of the foot caused by a fall of some distance upon the foot, one or the other malleolus may be broken off, and a vertical slit or fracture through the articular end of the tibia also result. In this case

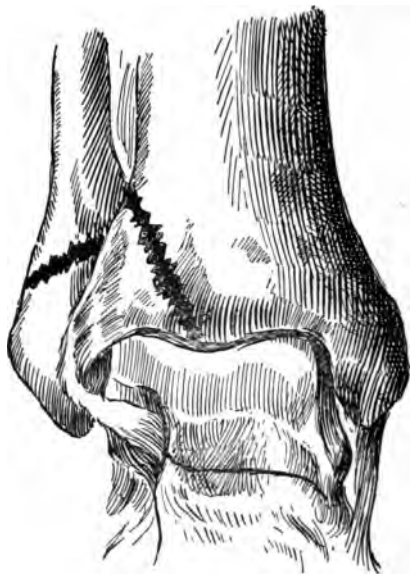

FIG. 50. Fracture of the external malleolus and articular surface of the tibia.

the astragalus may be driven upwards between the bones of the leg, and the fragment of the malleolus be widely separated and tilted, just as in a Pott's fracture. Usually the external malleolus is the one to suffer in such an injury. (See Fig. 50.) Some time ago I had such a fracture to treat. Under anæsthesia I tried by all manner of manipulations to restore the fragment of the malleolus to its place, but in vain. It was comparatively easy to get the astragalus and the accompanying fragment of the tibia to their places by extension of the foot and a little local manipulation, but I could not get the malleolar fragment to fit into its place. I could move it about

under the skin and fascia easily in various directions, but it was turned half on its axis, and "would not get right." Finally I cut down upon it intending to exsect it unless I could readily return it. I found the fragment wrapped about by shreds of fibrous tissue in which it was thoroughly entangled, and the peronei tendons under and back of it and clinging to its sharp edges. When these tendons were raised and pulled backward, there was no difficulty in replacing the fragment. The patient's recovery was uneventful and the function of the ankle-joint unimpaired afterward.

Treatment of these fractures should be conducted on the same lines as Pott's fractures.

I have had the fortune to be consulted about deformities resulting from unreduced Pott's fractures and other fractures resulting in serious displacements about the ankle-joint in many instances. One case came near being a very serious medico-legal one, and resulted in a suit for heavy damages for malpractice against a young practitioner of my acquaintance. I was consulted in this case several months after the original injury. The physician in charge was unable, after prolonged effort, to get a displaced fragment of bone, just under and pressing hard against the skin in front of the internal malleolus, back into place and left it there. In a short time the skin ulcerated, the fragment of bone sloughed out, the ankle-joint and tarsus were infected, and very extensive suppuration resulted. The man lost most of his tarsal bones, and the articular surfaces of his leg bones, and had a prolonged disability and a seriously distorted foot. In other instances permanent eversion of the foot and gradual giving way of the arch of the instep, with stiff ankle-joint, besides aching pain in the foot and leg, and permanent lameness have been noted. I know of few conditions more humiliating and distressing to an attending physician than these. I urge, therefore, the absolute importance

of thorough reposition of fragments, under anæsthesia, in these cases. If after careful and patient trial, one is not able to return the fragments to their proper places by external manipulations, he should cut down upon the fragment, and, if possible, loosen it from its entanglement of fibrous shreds and tendons and return it to its place, or else remove it at once through the incision. These unreplaced fragments just under the skin will surely result in harm, either to function or rapidity of recovery, and it is far better to remove them at once than allow them to remain in their false positions. Of course careful asepsis should be observed in these operations, and one should use his fingers, after the incision is made, in manipulating the fragment or retracting the tissue, as little as possible. It is better to use blunt instruments for these purposes as they can be thoroughly sterilized, and are more apt to remain so than are fingers.

FRACTURES OF BOTH BONES OF THE LEG.

In my experience fracture of both bones of the leg is more common than fracture of only one bone. Of the 232 fractures of the bones of the leg, 53 were simple fractures of both bones of the leg, and 71 were compound fractures of both bones. Thus it appears compound fractures are very apt to occur when both bones are broken, as one would naturally suppose on account of the close contact of the crest of the tibia with the skin.

The most common site of indirect fracture of bones of the leg is at or about the middle third. The tibia is usually fractured a little lower down than the fibula. Direct violence may produce fractures at any point, of course. As noted in discussing fractures of the tibia, children rarely have true fractures of the leg, except as the result of some direct violence; they do have separations of the epiphyses, usually the upper ones, as the result of indirect violence, however. A

transverse fracture of both bones of the leg is very rare in adults. The tibia may be fractured transversely, but the fibula is almost without exception obliquely broken.

In determining the proper treatment of fractures of both bones of the leg, the fibula may, as a rule, be

FIG. 51. Ordinary oblique fracture of both bones of leg.

left out of consideration entirely. The rule should be: restore the fragments of the tibia to their proper places and fix them there, and the fibula will be brought sufficiently accurately together to unite firmly. Comminution of the tibia may, however, require exceptional consideration to be given to the restitution of the fragments of the fibula. Also in some rare instances of very considerable inward displacement of the lower fragments, when the foot is driven outward, the sharp edges of the lower fragment of the

FIG. 52. Transverse fracture of both bones of leg.

fibula will require careful handling to prevent injury to the interosseal (peroneal) vessels and nerve.

Treatment of fracture of both bones of the leg may, therefore, be carried out almost upon the same lines as treatment of the fractures of the tibia. Practically these fractures may be considered as to the nature of the fracture of the tibia, viz., 1st, transverse, or 2d, oblique.

Transverse fractures of both bones of the leg are very rare, except as the result of direct violence. They should be treated as prescribed for transverse fractures of the tibia. (See page 156.) As a rule, forcible extension will accomplish more in reducing these fractures than when the tibia alone is broken. It should be remembered always to begin extension in the axis of displacement, and not change to the normal axis of the limb, until the ends of the fragments are thoroughly disengaged; else forcible locking of the fragments will result and extension will be useless. In fractures of both bones it is more necessary to put on a fixation apparatus at once after reduction than it is after reducing a fracture of the tibia alone; lateral movements and consequent displacement are much more apt to occur on account of the lack of support from the fibula. The photograph (Fig. 53), shows the deformity resulting from a partially reduced transverse fracture of both bones in the lower third of the leg. This case was seen by me first about eighteen months after the injury occurred. The history indicated a transverse fracture of both bones by direct violence (the patient was struck by a heavy rolling stone); no anæsthetic had been employed, and reduction was only partial; the anteroposterior displacement was marked, and the deformity was also marked. Union had taken place, but the function of the limb was almost destroyed because of the marked shortening and the very trying angle of displacement which made a pes equinus. Attempts

to bear weight on the foot resulted in so much pain that the patient did not attempt walking without crutches. This case required osteotomy—a wedge-shaped piece of bone was removed at the line of union and the foot brought into the proper axis.

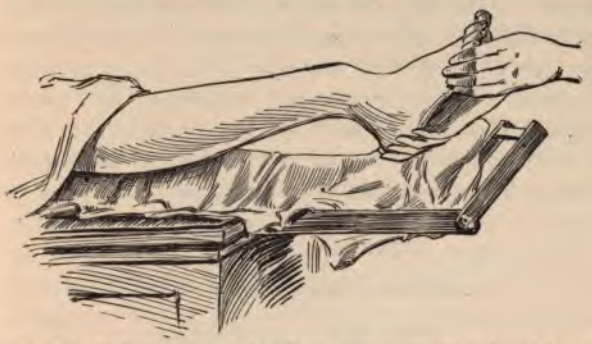

FIG. 53. Deformity resulting from only partially reduced transverse fracture of both bones of the leg.

Oblique fractures of both bones of the leg are the common fractures of this region. The middle third, then the lower third, and lastly the upper third are the order of their frequency. The upper third is rarely involved in these fractures. The fibula is usually broken higher up than the tibia. The obliquity of the fracture varies through nearly all the possible degrees and angles, and any part of the periphery of the bones may be the beveled part. One must, therefore, try to find out very carefully the lines of the fractured tibia, and accurately determine the displacement; as a rule, the whole endeavor should be to bring the fragments of the tibia into proper apposition; when this is accomplished the fibula will be sufficiently restored. The diagrams a, b, c, d, and e, indicate some of the most common lines of fracture of the tibia in oblique fractures. The displacements may be antero-posterior or lateral, according to the direction of the fracture. Fractures indicated by diagrams a, b, and c, if properly reduced, will remain in position if lateral motions are prevented. So any

simple apparatus will suffice to bring about a good result. Fractures of the kind indicated by diagrams d and e, are exceedingly difficult to treat without some shortening, and at least a little overlapping at the seat of tibial fracture resulting. I am frequently amazed at the easy breeziness with which embryonic surgeons speak of treating fractures of the bones of the legs with "perfect results." I defy any surgeon who has not had the greatest experience, and whose attention has not been called especially to this class of fractures, either by his own or some colleagues' apparent ill success, to treat fractures of the d and e

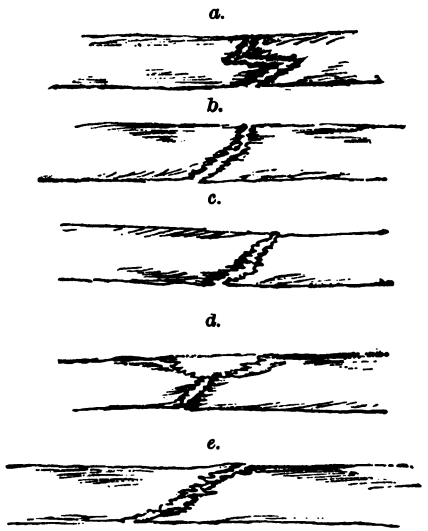

FIG. 54.

kind without some shortening, and a little local deformity, if the fracture has occurred in the bones of a strong, vigorous adult patient. I have great charity for my confreres, whose results as to "looks" have displeased their patients after treating these fractures. Luckily the functional result is usually good, even if shortening does take place and some deformity persists, but patients are too prone to object to "knobs" remaining in their legs after fractures, and they have

a most uncomfortable and unconscionable way of suing for damages. Fortunately, I have never personally had any experience as a defendant in court, but I have known other physicians who have had. I wish, therefore, to sound a note of earnest warning, and to urge my young, ardent and confident surgical brethren to be very careful never to intimate to a person having what seems a bad result after a fracture, that he has not received proper treatment. *Ex-post-facto* criticism is at best a very doubtful and unfriendly role.

General anæsthesia, as I have so often said, is especially useful, and, when there is no contraindication, should be employed in reducing fractures of the bones of the leg. (Two assistants are, as a rule, necessary therefore, one to administer the anæsthetic, the other to assist in manipulating and reducing the fracture.) After the patient is thoroughly relaxed, an assistant should grasp the foot of the injured extremity by the heel and ball, and make firm extension in the axis of displacement at first, and until the ends of the fractured tibia are disengaged; then, while continuing his extension, he should bring the limb to its normal axis while the surgeon in charge manipulates the ends of the bone into proper apposition. If there be much difficulty in drawing down the lower fragment, the leg may be flexed to a right angle at the knee-joint, and the thigh held up by the assistant while the operator makes extension at the foot; as a rule, this manœuvre results in bringing the fragment down. If it be a transverse fracture of the tibia, or one of the varieties represented by diagrams a, b, and c, the reposition will continue unless decided lateral movements occur, and the extension may be relaxed and the apparatus applied at once. If, however, the fracture be of d or e variety, the trouble has just begun; it is almost impracticable by manual extension to keep the ends of the fragments in proper position; pulley extension is

frequently impracticable or unavailable. On the whole, I think I prefer the manual extension. When the assistant has drawn the beveled ends down so they fit well together, I direct that he jam the rough fractured surfaces together by carrying the foot forcibly in the direction of the superficial beveled surface, usually inward or upward. This assists materially in holding the surfaces together. Having previously prepared some moulded thick cardboard, leather or tin (this last is best if plaster-of-Paris is to be used) apposition splints, well padded, these are placed accurately on either side of the leg over the seat of fracture, and immediately fastened in place by rubber adhesive strips. These splints should not be wide enough to envelope the whole periphery of the limb, and should be long enough to extend about 10 cm. above and below the fracture. This further fixes the bones. Now a plaster-of-Paris dressing should immediately be applied from the toes well up to the

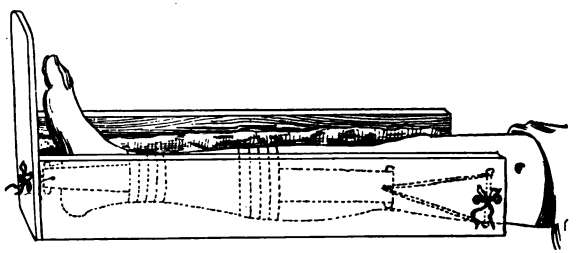

FIG. 55. John Neil's apparatus for extension and counter-extension of the leg.

knee, and be made to fit especially accurately about the heel, malleoli and the tuberosity of the tibia, so that the extension, which must have been continued, shall be made permanent when the plaster dries.

Another method of treating these oblique fractures is by an arrangement for permanent extension similar to John Neil's apparatus shown in Fig 55. An ordinary old-fashioned fracture box, with moleskin adhesive plaster and some rubber tubing, will serve the purposes of this apparatus.

As I said, however, in writing of the treatment of fractures of the tibia, I am convinced the best treatment for these beveled and very oblique fractures is the *open method,* namely, incision, clearing off and accurately replacing the fragments, and hold them firmly in place by ivory or steel nails, or by my nickel-plated fixation plate. After this a firm plaster-of-Paris dressing should be applied.

The primary dressing or splints should remain on after fractures of both bones of the leg for about two weeks, then be removed, and the seat of fracture be inspected; if all has gone well, and the reposition remains good, the same plaster-of-Paris splint may be continued, or if this has become too loose or does not fit properly, another one should be applied After this the patient may be allowed to get out of bed, and in a day or two be allowed to go about on crutches. In five weeks from the time of fracture the dressings should again be removed, and massage and passive movements at the ankle-joint be employed, after bathing the skin of the leg with alcohol. As a rule, fairly firm union will have taken place. A light dressing should be continued for another week. This dressing should be of such a kind that it may easily be removed and daily massage and movement at the ankle-joint be employed. After six weeks, as a rule, all stiff dressings may be discontinued, and the patient be instructed to very gradually begin to walk on the extremity again by first using his crutches and then a cane. Seven to eight weeks usually suffice to effect a cure, though many patients require two or more weeks longer to regain good use of the limb. In cases of very oblique fracture the patient should be cautioned to be very careful to use the extremity very gradually, and not allow his full weight on the injured extremity but for a very short time at first, and gradually longer periods each day. He should be very careful not to step into holes or upon unequal surfaces and not to fall, as these accidents

frequently wrench the fragments asunder. In cases of very oblique beveled fractures I think patients ought to be warned that unless they elect to have an operation of local fixation done, they will probably have a little overlapping and slight deformity at the seat of fracture.

FRACTURES OF THE BONES OF THE TARSUS.

The astragalus and os calcis are the only bones of the tarsus the fractures of which deserve separate mention.

The astragalus is not infrequently broken by indirect violence. As mentioned in writing of the fractures of the malleoli, this bone is commonly fractured by landing on the feet in falls from heights. The fracture is usually transverse in these cases. The usual location of the fracture and its general direction is indicated in the diagram, Fig. 56, by the line a b. Sometimes there is very little displacement, and the diagnosis is difficult without the use of X-rays. Many other cases show very decided and disagreeable displacement. The head of the bone and the anterior part of the articular surface is frequently driven forward and inward into the space between the inner malleolus and the tendon of the tibialis anticus muscle. This fragment is furthermore tilted so that its posterior or a lateral edge is turned upward. The tibialis anticus tendon may be pressed outward, or the fragment may lodge under the tendon and be firmly fixed by the spasmodic pressure of this tendon over it and the extenser pollicis on its outer side. In such a case it is almost impossible by any ordinary manipulation to return the fragment to its place. In these displacements the fragment lies just beneath the skin, enwrapped by shreds of the anterior and a portion of the deltoid ligaments. The pressure on the skin is very great, and unless quickly relieved is apt to result in sloughing.

Treatment of fractures of the astragalus without displacement is very simple. Rest and any simple light fixation apparatus will do. Many surgeons treat these fractures by simple rest on a pillow or cushion, with perhaps a roller bandage to prevent excessive swelling. I prefer to fix the ankle-joint and to immobilize the tarsus. A light plaster-of-Paris bandage, I think, is the best for this. It should extend from the toes to the lower third of the leg. After the expiration of two weeks it should be removed, and passive movements at the ankle-joint be begun. These movements after this should be employed daily. The patient should not be allowed to walk on the injured member for at least three or four weeks, as the pressure of his weight is apt to drive the anterior fragment forward and permit the articular surface of the tibia to glide forward, thus, in time, causing a relaxation of the scapho-astragaloid ligaments, and finally the arch of the tarsus will be reduced and a persistent "flat-foot" result.

Fractures of the astragalus with displacement of the anterior fragment, as indicated, should be promptly treated in order to save the skin. Reposition of the displaced fragment will be very difficult, as a rule, and excessively painful. General anæsthesia should be employed. When the patient is thoroughly relaxed an assistant should catch the foot by the heel and ball and make traction downward and flex the foot; the operator should now attempt by gentle, direct pressure and manipulation to push the fragment into its proper place. If this does not succeed in a short time, he ought to cut down upon the fragment, raise the restraining tendons, push aside the shreds of the torn ligaments, etc., and having, as far as possible, cleared the way, gently push the fragment backwards by means of a light sequestrum forceps. If this cannot be done then the fragment should be removed at once. The fingers should be used in the wound as little as possible; instruments

previously thoroughly sterilized should rather be employed, in order to lessen the chances of suppuration. After reposition or exsection of the fragment the treatment is practically identical with cases not operated on.

In case of a wound having been made, careful aseptic dressing without drainage should be applied, and then a plaster-of-Paris fixation dressing. This should be continued for four weeks, then be removed and passive motions employed afterward. A supporting brace should be used for several months after

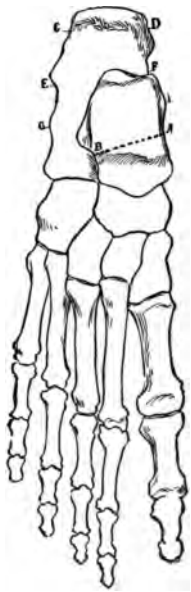

FIG. 56. The line a, b, indicates the location of the most frequent fracture of the astragalus; c.d., e.f., g.h., indicate the usual points of fracture of the os calcis.

exsection of the displaced fragment of the astragalus to prevent giving way of the arch of the foot.

Fractures of the os calcis are due generally to direct violence. Very rarely they may occur from violent contraction of the calf muscles, but I cannot recall any case of this kind in my own experience.

Except in crushing injuries, displacements after fractures of the os calcis are not very marked. Treatment will, therefore, consist largely in attending to the accompanying wounds of the soft tissues, and simple fixation of the foot. It is well to remember that the foot should be placed and kept in a position about a right angle with the leg. The tendency is usually for the foot to be held in an extended position. If allowed to remain in this position it will be very difficult to overcome the chronic spasm of the calf muscles afterwards. This spasm may also result in drawing the posterior fragment upwards, and a condition of talipes equinus result. After-treatment and the time of wearing the splint should be about the same as after fracture of the astragalus.

Fracture of the other tarsal bones should be treated as an injury to the whole tarsus. These fractures usually result from some direct violence, and except in serious crushes, rarely have marked displacements. Careful manipulation should be employed to overcome any tendency to downward displacement, and a plantar splint, padded firmly with a convex pad, in order to preserve the arch of the foot, should be fixed in place by a plaster-of-Paris roller bandage. The splint should remain on for two weeks, then be removed and the arch inspected. If the union is fairly firm the plantar pad may be fixed by adhesive plaster straps and a muslin roller, and the member be given rest for ten days or two weeks longer; after this the patient should wear a broad-soled, laced shoe, having a plantar arched support, and continue its use for several months.

Fractures of the Metatarsal Bones.—These fractures are due to direct violence. The chief endeavor should be to prevent the ends of the fragments projecting downwards into the sole of the foot, and laterally upon the nerves. Very painful after-conditions may result unless this is carefully attended to. Circularly constricting bandages should

not be used unless with a plantar splint, and this splint should be carefully padded to conform to the concavity of the sole and give sustained and equable support. The splint must be a little wider than the foot in order to prevent the bandages squeezing the fragments into the interoseous spaces.

Fractures of the Phalanges of the Toes are also due, as a rule, to direct violence. It is difficult to use individual splints for these fractures unless the great toe be the injured member. A wide piece of crinoline saturated with a "cream" of plaster-of-Paris or liquid glass, may be moulded on and serve efficiently, however, over all the toes, except the great toe. When the great toe is the member injured the fracture may be treated individually. As this is practically the only useful toe in persons who have worn shoes all their lives, it is well to carefully splint the phalanges with any easily moulded material. I like sole-leather, moulded on while moist, held in place by rubber adhesive plaster. Pointed-toed shoes should be avoided for some time afterwards.

COMPOUND AND COMPLICATED FRACTURES

Antiseptic and aseptic methods have robbed fractures complicated by wounds, or those requiring serious wounds and explorations for their proper treatment, of much of the seriousness which formerly always belonged to them. The mechanics of their treatment must be modified by the wounds, and the degree and extent of the injury, not only to the bones but also, and frequently chiefly, to the soft tissues.

I shall not attempt to consider these injuries with reference to each individual bone, but shall make two classes of them, namely: First, Complicated and Compound Fractures of the Cranium, and secondly, Complicated and Compound Fractures of the Bones of the Extremities.

If there be any special reason for the existence of railroad surgeons as a class, or the division of surgery

into a special branch called railway surgery, the chief claim for these specialties, in my judgment, lies especially in the fact that railway injuries are almost uniformly multiple and greatly complicated, and that some especial experience is needed to properly estimate the extent of these injuries, and to suggest and employ the best means of meeting the multiple indications. In this era of heavy and rapidly moving machinery, factory and mine accidents are also, as a rule, of a nature similar to railway accidents in that they too result in multiple and complicated injuries. It follows, therefore, that the treatment of injuries from modern machinery requires much more, in every way, and differs materially from the rules laid down for ordinary wounds and fractures in the older books. What is true of these injuries generally is especially true of fractures occurring on the railroad, and in factories, and mines. Of course, many simple fractures also occur, but the majority of the severe accidents produce complicated fractures. This section has to do only with what the German writers term *complicated fractures*, meaning thereby fractures which are not only compound, comminuted, or attended with severe injury to the vessels and nerves of the fractured limbs, but which are these and much more besides, as they usually are accompanied by very severe comminution or laceration of the neighboring soft tissues, and almost without exception by other injuries, many of them severe.

COMPOUND AND COMPLICATED FRACTURES OF THE CRANIUM.

As the treatment of some fractures will depend largely upon the history of the injury, it is well to start out with a division of fractures into two classes, namely: (1) fractures from direct violence, and (2) fractures from indirect violence. In my experience, this may be put in another way and be stated: (1) fractures of the vault of the cranium, and (2) fractures of the base of the cranium. There is no doubt in my mind that the old ideas of the mechanics of indirect

fractures of the cranium do not explain the post-mortem or operative manifestations. In all my experience I cannot recall or find a record of a single example of fracture by "*contrecoup*" in the sense of the older writers; namely, a fracture produced by "vibrations meeting at a point opposite that struck." Aran's law of fissures extending, by radiation, from the point struck to the base, will also not explain the nature of many cases of fracture. The "*bursting* theory" adopted by many German writers, and by Musser in a modified degree, seems to meet the conditions I have most commonly found, and the cerebral conditions are best explained by the theory of Duret, as amplified and extended by Dr. Roswell Park.

The fact that basilar fractures are produced usually by indirect violence, and those of the vault invariably by some form of direct violence, must largely enter into the ideas of proper treatment, because, and especially, the indirect fractures are *fissured fractures*, and direct fractures are those which are depressed. This last statement should not be construed to mean that *all* fractures of the vault are *depressed* fractures; this, of course, is not the case, and I do not intend to convey any such idea. While, in my experience, basilar fractures occur usually from *indirect violence*, and are in such cases invariably *fissured fractures*, the fractures of the vault occur rarely, *if ever*, as the result of *indirect violence*, but they may be either simple fissures or depressed fractures of any degree of severity. Unless the case be a clear one upon examination the treatment will largely be dependent upon whether the injury occurred as the result of direct or indirect force.

Clinically, complicated fractures of the cranium may be classified as follows: 1. Simple depressed; 2. Fissured; 3. Compound. This last class will be made to include all the usual varieties of compound fractures; *viz.*, comminuted, depressed, and mixed conditions, as for instance, compound-comminuted depressed fractures, etc.

Simple Depressed Fractures.—There may be one or two conditions, absence of both, or a combination of the two after these fractures; namely, 1, compression; 2, laceration of the meninges and brain; and 3, both compression and laceration. The compression may be from hemorrhage or from the impaction of the bony fragments upon the cortex. If the case is

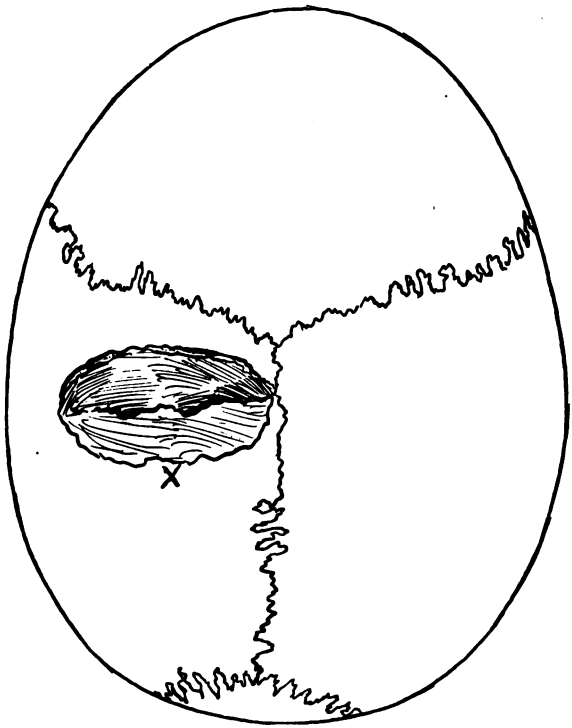

FIG. 57. Depressed fracture of the outer table.

seen some hours after the injury, it is sometimes a very difficult matter to decide whether the signs of the compression be from hemorrhage or from the displaced fragments. I have found that localization symptoms and signs are much more pronounced, and the area implicated smaller if the compression be

from the depressed bones alone; the brain accommodates itself much quicker, and the signs of compression are apt to be transitory, and the patient regains consciousness much more rapidly than when the compression is from hemorrhage. If the history can be obtained, the fact that complete unconsciousness supervened after a period of complete or partial consciousness, immediately or soon after the injury, and that it became progressively more pronounced, would make the diagnosis of hemorrhage, taken in connection with the other well known signs, easy.

Mo lern surgeons recommend an *operation* for compression after an injury, almost invariably. While

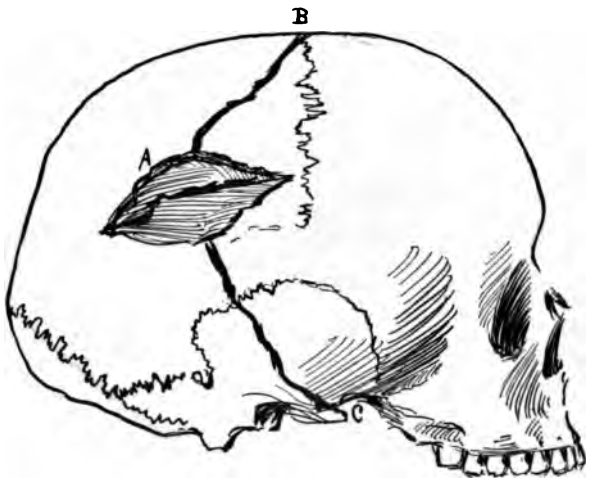

FIG. 58 Depressed and fissured fracture of the inner table.

accepting this as the safest rule, since the operation, when properly performed and *rightly directed,* will certainly add nothing to the dangers of the case; I would suggest a marked element, in *this* variety of fractured cranium especially, which should always be considered. I refer to the possible injury wrought by the wave in the cerebro-spinal fluid which must occur when injuries of this kind are received. The elastic bones of the cranium at "the cone of depres-

sion" transmit a marked impulse to the fluids within the cranium, and these, driven in a rush from the lateral and third ventricles through the narrow aqueduct of Sylvius, pour a narrow but powerful stream suddenly upon the vital fourth ventricle, and this impulse, according to Duret, who was one of the first to recognize this element, by overstimulation of the restiform bodies causes an "anæmia of the brain." This impulse may do far more harm; it may also

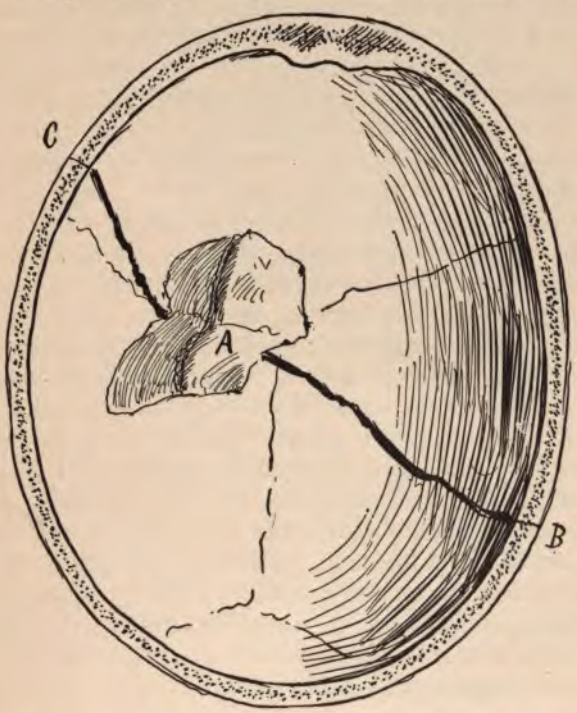

FIG. 59. Depressed and fissured fracture of the inner table.

cause contusions and lacerations in the neighborhood of the ventricles and affect directly the deeper ganglia of the brain. In this case *diffuse* signs and symptoms with well marked physical signs of compression might be manifest, as after subdural or subarachnoid hem-

orrhage. In such a case the ordinary operation of opening the cranium and dura mater would not result in any good whatever. This deep injury is frequently combined with subdural hemorrhage. Some time ago I had a case in the hospital which had an injury in the right parietal eminence, but all the signs and symptoms pointed to an injury of the motor area in the cortex of the left hemisphere of the cerebrum. I accordingly not only raised the depressed bone at the seat of injury, but trephined on the left side. There was no sign of injury to the bone or dura. Upon opening the dura the subdural space contained much fluid blood, which was evacuated; there was no clot found anywhere. The symptoms were not relieved and the man died. Post-mortem showed numerous hemorrhages into the left cortex, and the ganglia about the left lateral ventricle. An operation for hemorrhage which is not directed by clear, well defined and *localized* pressure symptoms, must be at best a tentative measure, and while it always avails when there is a well marked subcranial clot, it is simply contributory in the usual cases of diffuse subdural hemorrhage, and recovery, if it occurs, is only after the absorption of many clots (scattered, as a rule, throughout the side of the brain opposite the injury), and is usually very slow and tedious. Operation for depressed fractures with well marked pressure symptoms is always indicated, however. With well marked localized symptoms it usually suffices to raise the depressed bone, using an incision through the scalp which will best assure perfect drainage. It is very rarely necessary or expedient to use a trephine; a chisel, a stout rongeur, and an elevatorium are better adapted to clear out the depressed bone. The immediate surroundings of the depressed area should be carefully explored to be quite sure that the inner table has not been splintered and depressed some little distance beyond the depression in the outer table. Lacerations of the dura in these cases are rarely severe

and require no suturing, as a rule; hemorrhage is rarely of any consequence and may be controlled by packing with iodoform gauze.

In a case of diffused symptoms and signs of marked respiratory disturbance, there will usually have been subdural hemorrhage, and very likely multiple hemorrhages into the cortex and about the lateral ventricle of the side opposite the injured side. Sometimes trephining on the side opposite the injury and opening the subdural space, with thorough evacuation of the blood and clots, if there be any, will relieve pressure upon the cerebellum and medulla, and assist in the ultimate recovery, which will be very slow, if it occurs at all. These cases have very bad prognoses. A suggestion of Dr. Edmund Souchon, to use capillary punctures of the ventricles, might with advantage be employed in this class of cases. I have so far never employed it, but in a suitable case expect to try it. As a rule, the comminuted depressed fractured bone should not be returned; some form of heteroplasty may be employed if the case admits of perfect drainage. The trephine button on the side opposite the injury may be returned after nicking the edge of the opening at its most dependent part, and inserting a capillary drain at this place. One of the most essential things to bear in mind after all offending bone and blood have been removed, is drainage. There is always much contusion of the brain in these cases, and there will be much effused serum and blood in the cranial cavity to escape after the evacuation which is obtained at the operation. Clean shaving, thorough cleansing and disinfection of the scalp must always be employed as a preliminary to any operative measure. As a disinfectant, I think a five per cent. solution of carbolic acid or 1-1000 formalin solution is a more efficient germicide in rapid preparation of the scalp for operation than sublimate solutions. I am convinced that Lister is right in asserting that when there are a multiplicity of epidermal scales and much sebaceous matter, carbolic

acid permeates better, and the staphylococcus albus is much more apt to be killed by its use than with corrosive sublimate, which precipitates albuminous matters, and on this account is prevented from entering the deeper crevices of the skin. The after-treatment of these cases will be considered later in connection with compound fractures.

Fissure Fractures.—These fractures may, and do involve any part of the cranium, but are of little consideration, unless very extensive, when they involve only the vault. As complicated fractures, they belong to the base of the cranium and are, when in this region, produced by indirect force. Aran, in elaborating his law of radiation, as an explanation of indirect fractures, stated that basilar fractures usually extended from the vault, where the force was applied, to the base. My experience has exhibited a number of cases quite different. I have in mind at present a very striking case of basilar fracture of the anterior and middle fossæ on the right side, which resulted from a blow on the left side of the vault (at the parieto-occipital region of the left side) and at the post-mortem showed a very extensive fissure leading up through the temporal and parietal bones on the right side. At the base there was considerable separation; above, the separation was so little that the fissure could scarcely be seen until the dura was stripped off the bones. A number of less extensive fissures of this kind, all exhibiting similar features, have convinced me that the "bursting" begins at the base and extends upwards (as a rule) in these cases.

Fractures of the base of the cranium when *recognized* are nearly always *compound.* I have reason to believe that many fractures of the base occur which we, at the time, do *not* recognize, but diagnose as cases of severe concussion. Indeed, the pathognomonic signs usually given in the books as characteristic of basilar fractures, are only possible when

these fractures have implicated one of the cavities of the face or head and have thus become compound. The problem is, therefore, how best to treat a compound linear fracture of the base of the cranium.

Treatment of Basilar Fractures. Luckily these fractures occur most frequently in the anterior and middle fossæ. Luckily, because these fractures occur as the result of great violence and there are always multiple contusions and lacerations of the brain, and frequently of the membranes, and such injuries are much more serious about the pons and medulla than about the base of the cerebrum. I believe, therefore, there are two factors to be considered in treating basilar fractures; the first and most immediate is the fracture, which is usually compound, and the second, the badly injured base of the brain. This latter injury consists of multiple small lacerations and hemorrhages, not microscopic but easily seen and appreciated by the unaided eye, and severe contusion of the brain, which means laceration of capillaries, effusion of blood, infiltration of serum, and edema later on.

The great difficulties in the proper treatment of basilar fractures are (1) obtaining asepsis and (2) securing good drainage.

Until recent years these fractures were left to the kind efforts of nature alone, and the prognosis was very bad. I am accustomed now to make careful efforts to disinfect the implicated ear or nostrils, and to employ a filtering and occluding dressing as soon as the case is received and the condition recognized, and in order to secure as good natural drainage as possible, tight plugging of these cavities is sedulously avoided. My results with this treatment have been very good.

The technique of these cleansing and disinfection efforts is very simple, but should be very carefully carried out. As soon as a case of basilar fracture is brought in, both ears are examined as well as the

nostrils, and having determined that only one ear is affected, this is at once carefully washed outside with green soap and warm water, the external meatus and canal also, then carefully douched with a weak solution of sublimate (1-5000), or with a 1-5000 warm solution of formalin, then with a warm normal saline solution, and then if the drum is ruptured sufficiently, a narrow strip of sterile iodoform gauze is introduced into the middle ear, other iodoform gauze placed in the auditory meatus (not plugged firmly into the external canal), and the whole ear is covered with sterile absorbent cotton and this held in place by a bandage. The patient, who is usually unconscious, is kept as much as possible turned toward the affected side in order to permit the bloody serum to gravitate in this direction as freely as practicable. If the fracture has implicated the nostrils (when there has been considerable *thin pale* blood discharged from the nose it is best to take it for granted that they are involved), they are immediately cleansed by gentle swabbing with loose pledgets of gauze moistened in a saturated boric acid solution, carefully douched with a saline solution, containing some oil of eucalyptus, carbolic acid and camphor water (about five-tenths per cent. oil of eucalyptus and one per cent. carbolic acid), and *sprayed* carefully with this solution; then both the anterior and *posterior* nares should be closed with sterile iodoform gauze. The middle part of the nostrils and especially the upper part near the cribriform plate of the ethmoid is left free, so that the discharges may make their way through the fissure unimpeded. The anterior dressing in the nostrils usually requires daily removal, the nostrils being gently cleansed again, the spray used, and the gauze replaced. The posterior "plug" may remain for several days. The ear dressings require to be changed about every second day, but no further douching should be employed unless there has been a rise of temperature.

Should the temperature rise and pressure symptoms increase, the temporal fossa low down anteriorly and the region just anterior and above the external ear offer the best places for drainage for the anterior and middle fossæ fractures. It is almost impracticable to drain the posterior fossa. Small trephines and capillary punctures of the dura should be employed in making basilar drains, unless pus be present, in which case the dura must be freely opened.

The after-treatment of the cerebral injuries consists in maintaining drainage, and functional rest for the brain itself. I am accustomed to give sufficient morphia hypodermically to keep the patient quiet and somnolent, and I have found, or thought I have found, bichloride of mercury, given internally, as freely as the patient will bear, of great assistance in promoting absorption. I have found strychnine a much more valuable and reliable respiratory stimulant than atropine in cases where the respiration is badly affected. Besides the atropine is apt to excite the brain too much when it is of the greatest importance to quiet the mental state.

Compound Fractures of the Cranium.—The treatment of these severe injuries should be upon the same principles as complicated fractures elsewhere. The cranial cavity is no longer the "*nolle me tangere*" of surgery. With asepsis and *thorough drainage*, results which formerly were considered quite impossible are now being obtained by every modern surgeon. The majority of the points I shall endeavor to make will seem trite and familiar to surgeons accustomed to this work, but for the sake of encouraging the general practitioner (especially the *country* practitioner, who is most frequently called upon to handle these cases unassisted) to treat these cases with some confidence, I shall go into some of the elemental features of the technique of treatment.

First Aid.—Unless the surgeon is prepared to do any necessary operation for the cleansing, disinfection,

removal of offending pieces of bone, suturing the dura, after evacuating lacerated and detached cerebral tissue, he should confine himself to efforts for the control of hemorrhage and the prevention of further soiling of the wound. When he renders first aid, the wound should never be explored further than to separate the hair, and by *means of the hair*, the lips of the wound very gently and carefully in order to discover the extent of injury. Soiled fingers "poked" into a cranial wound have many a time signed the death warrant of the injured person, and the knowledge gained by touch has rarely been of any service in the immediate handling of the case. If there is free hemorrhage it ought to be checked. There are two possible sources of this hemorrhage: (1) The vessels of the scalp, and (2) the intra-cranial vessels. Exploration of the wound at this time should be only to find out whether the bleeding is from the scalp or from within the cranium.

Usually scalp hemorrhage may be controlled by placing a thin compress under the surface of the wounded scalp and another above the surface, and by a bandage gently squeeze the edges of the scalp between the two. The hands should be carefully washed before doing this manipulation, and only the least possible manipulation be employed. In other words, the condition of the wound should be disturbed as little as possible. The compresses should also be perfectly clean, if practicable, sterile. Unless means be at hand for *thoroughly* cleansing the wound and its surroundings, it is best not to attempt it at all. If the hemorrhage is from the inside of the cranium, or from the diploë, packing must be used, if the bleeding is at all severe. Pack the crevices between the fragments of the bones with some clean, thin fabric, gauze is best if it can be obtained, and then fill the whole wound with the same material tightly and bandage firmly in place. Then the patient should be transported to a place where

he will receive permanent care and attention as soon as possible, and his head kept a little elevated during the journey.

These injuries always require an operation. Frequently the operation will be only raising a little depressed bone and suturing the scalp after most careful cleansing; occasionally, however, it will be necessary to remove a quantity of comminuted bone, clear out a quantity of lacerated cerebral tissue, stop profuse hemorrhage, attempt to restore or replace lacerated dura, provide for deep drainage, do some heteroplastic operation to prevent a subsequent hernia of the brain, and transplant the scalp to cover the opening in the bones.

Operation Technique.—When the surgeon is ready for the permanent dressing and operation, the first act, after getting the patient in a suitable light upon a proper table, should be to clip, with a scissors or *hair clipper*, the hair about the wound, and then rom the wound outwards over the whole scalp, or over so much of the scalp as will assure absolute safety from any infection from the hair. During this clipping the wound should be covered by a piece of sterile gauze. Now the immediate surroundings of the wound for some distance about it should be shaved after careful lathering with green soap. Care should be used to shave in *a direction away from the wound*, and while wielding the razor the flaps of the scalp should be steadied by gentle pressure. Now the patient may be chloroformed. (I think if there be no organic heart lesion chloroform is better than ether in these cases.) Even if he be seemingly unconscious the patient is apt to have so much reflex left that manipulations will produce struggling. When he is under the anæsthetic, have an assistant to carefully douche the wound with a warm, sterile, normal salt solution, and thus wash away detritus, clots, hair and dirt from the wound itself and its immediate surroundings. During this time the operator

and his chief assistant should thoroughly scrub and sterilize their hands. The first assistant, after irrigating the wounds and surroundings, should place over it sterile gauze and carefully hold it in place while he washes with green soap and water the whole scalp, then use ether and alcohol to remove sebaceous matter, scales, etc., then a warm five per cent. solution of carbolic acid, or 1-1000 formalin solution, and lastly the sterile salt solution. Place the head on a firm, sterile, rubber covered pillow, and now again irrigate the wound carefully with the sterile, warm salt solution. The surgeon may now begin his exploration and operation. The instruments, of course, should have been thoroughly sterilized, and they should be kept in a warm, weak solution of carbonate of sodium, during the operation. My experience, as well as that of other surgeons accustomed to operate for head injuries, suggests the "bull" that in "*trephining*" for depressed compound comminuted fractures *never use a trephine.* The instruments necessary are a knife, a pair of blunt-pointed scissors, a chisel, a good, sharp, strong Hopkins rongeur, two or three bone forceps with different curves, an elevatorium, two thumb forceps, one "rat-tooth," a half dozen hemostatic forceps, small and medium sized curved needles, and a good needle holder, small and medium silk, silkgut and catgut for sutures and ligatures. The small needles should be previously threaded and ready for instant use.

The operation is begun by incising the scalp over an area sufficient to expose freely the depressed bone, following the line of laceration as far as practicable. Rapidly raise and separate the scalp and pericranium from the bones, catch every bleeding vessel in the scalp, turn back the flaps, chisel or gouge the edge of the peripheral fixed bone to get under the edge of the depression with an elevatorium or bone forceps. The depressed bone should be slowly and carefully lifted up. If the fragments have been much soiled,

as they frequently are, they should be removed entirely; if not at all soiled the question of their removal will depend upon the condition of the fracture; if very much comminuted and displaced, and the dura and cerebrum much damaged, they should, as a rule, be entirely removed and be kept in a warm, sterile, saline solution with the idea that in certain cases they may possibly be replaced. With the removal of depressed bone, hemorrhage will occur if any principal vessel is involved. This sometimes is a most formidable complication when a sinus is injured or the middle meningeal artery be torn low down. As soon as the bone is out and hemorrhage is free, press into the wound a pledget of sterile gauze and hold it firmly in place for a few seconds, then raise it gradually from one side and carefully watch for the exact spot from which the blood flows, or from which occurs the most profuse flow. If it comes from the dura a stitch passed by the small curved needle already threaded, will probably control it unless the dura be very badly lacerated. I have had two cases in which the hemorrhage was so exceedingly profuse when the depressed bone was raised, that I was obliged to desist, rapidly pack with iodoform gauze, and give up any further operative attempt. One case was an enormous fissure and depressed fracture in which the whole parietal bone was driven downwards upon the cerebrum and the temporal bone fissured transversely across. The bleeding from the meningeal vessels was so profuse nd from so many places that raising the bone would have meant almost immediate death. The bone was left depressed and acted sufficiently, with external plugging and compression, to control the hemorrhage. The cerebrum was so extensively torn that the man soon died, nevertheless. The other case was quite an extensive compound-comminuted fracture, just a little posterior and to the right of the vertex. The depressed part had torn the longitudinal sinus. The

first gentle movement of the depressed fragments was followed by a torrent of blood. I was obliged to drop the fragment back immediately and make pressure; then with a gouge and chisel I cut out some of the peripheral fixed bone, succeeded in detaching a small fragment of loose bone near the sinus, and by gently insinuating a piece of iodoform gauze in the direction from which the blood seemed to come, I finally stopped the hemorrhage. The next day I was able to raise the depression, but the hemorrhage was again profuse. I controlled it, however, by packing gauze into the rent in the sinus. The man made an uninterrupted recovery, notwithstanding the very extensive depression and loss of bone. These cases show that even the most alarming hemorrhage may sometimes be controlled, and packing is the most efficient method of doing this. Such cases as these also show the necessity of having ready means of meeting these emergencies and the futility of attempting these cases by the roadside or when not prepared for them.

The fragments of depressed bone having been removed and the hemorrhage stilled, the next thing is to clean out clots and all detritus. I find a gentle stream of warm, sterile saline solution the best method of doing this—especially when the dura is badly lacerated and there has been an escape of lacerated cerebral matter. Swabbing out a cavity in the brain is a disagreeable and rough method, and is apt to increase the injury and do great harm. After this, if practicable, the dura should be sutured with fine sterile silk. If the dura cannot be brought together and especially if the cortex has been lacerated, there is great danger of cerebral hernia resulting. In these cases I have *replaced* the dura with a layer of *gold foil, introduced under the edges of the dura on every side,* and of course large enough to cover the area of bare brain left by the lacerated dura. The dura holds the edges of the foil, then by passing sutures from one

edge of the dura across the foil to the other edge and tying them, it is held firmly in place.* I wish to lay especial stress upon the importance of inserting the foil *under the dura mater;* if the arachnoid is intact it lies between the dura and arachnoid. Other operators (notably Dr. H. H. Beach, of Boston) have used the foil between the dura and cranium for the purpose of preventing adhesions to the bone. Experience has shown that in traumatic epilepsies there are nearly always adhesions between the *dura and the arachnoid and pia,* and that fibrous bands seem attached *actually* to the cortex itself. The expedient I recommend will obviate these deep adhesions to a great extent, as well as fill in the gap in the dura. When the force applied is very great and over a very circumscribed area, as by a blow from the cork of a horse's shoe, or a bolt on a car striking the cranium, there may be a sort of punched out wound of all the tissues and a depression deep into the cortex, as I have seen in one case. After all bone, detritus, etc., is removed, there will be a *cavity* left in the brain, and the cerebral tissue, semi-solid as it is, will continually gravitate into this cavity and thence outwards, in spite of all ordinary efforts to prevent it. I succeeded in controlling this and had a rapid recovery in the case I mentioned, by making a cup of the gold foil and sinking *it into this cavity in the cerebrum, about 2 cm. deep;* by attaching its rim to the indentations and irregularities of the inner table I anchored it and then gave it fixidity by plugging the cavity of the cup with iodoform gauze. I would heartily recommend this in similar cases and shall use it whenever I have a chance. The gold foil remained *permanently* in the cerebrum and caused not the slightest disturbance, and prevented absolutely any further escape of cere-

* See my paper published in *Medical News*, March 10, 1894, and one read before the Academy of Railway Surgeons at the 1895 meeting.

bral matter. The gauze packing may be removed in three or four days.

Having dealt with the dura and lacerated brain according to the indication, the next point is to assure good drainage. Usually capillary drains of iodoform gauze or thoroughly sterilized catgut will suffice; these, while they act as *capillary* drains, are best placed at the most dependent part of the wound when the patient shall be in the ordinary recumbent position in bed. Gravity will assist in draining, and sometimes this is necessary in such cases. The next question is, shall the pieces of bone be replaced or not? When the fragments of bones are all badly comminuted, especially when *they have been badly soiled,* and when their replacement may possibly interfere with drainage, *do not replace them.* Indeed, my experience is against replacing the fragments at all when they have been entirely separated. They are almost sure to become *depressed,* no matter how carefully and nicely they be replaced. In one case, traumatic epilepsy followed after such replacement, and though it was subsequent to a second severe injury to the head, the symptoms now all point to the firm but depressed area where the fragments were replaced, and I think these are causing the trouble. The man absolutely refuses to have an exploration made. I think Dr. Beach's and Weir's recommendation of gold foil under the cranium—or some of the other heteroplastic methods, such as plates of celluloid, ivory or silver fitted into the space left vacant in the cranium, should be used.

The scalp should, as a rule, be nicely apposed and sutured, leaving always a sufficient space for the drains. Sometimes extra drains through the scalp may with good effect be used. Sterile, dry dressings should be applied and held firmly in place by careful bandaging.

After-Treatment.—The after-treatment of cases of cranial injury, followed by operation, is usually very

simple, if the operation has been efficient. Cases of depressed fracture or fissures of the vault are frequently accompanied by pressure signs rather diffuse, but in many cases pointing to injury of the side opposite the injury. In these cases subdural hemorrhage or multiple small hemorrhages, small lacerations, and severe contusion of the cerebrum in the cortex and about the corpus striatum and optic thalamus of the opposite side may be suspected. Trephining over the motor area of this side, incising the dura, and occasionally capillary drainage of the lateral ventricle may be of service, if the original operation failed to give relief. This secondary opening should be done with a *trephine* or electric saw and *not with a chisel*, as jarring of the head should be sedulously avoided. For 24 hours after the operation I am accustomed in the hospital to give pretty full doses of ergot and the bromides; also full doses of mor phine hypodermically if restlessness or sleeplessness should require it. A prime indication is to keep the patient quiet and absolutely free from pain if possible. I never use ice caps or any application of cold to the head after head operations. Gauze drains may be withdrawn as a rule in 48 hours. Gauze packing for hemorrhage, unless a sinus or one of the larger meningeal arteries has been torn, may be removed at this time also. If one of the larger vessels has been involved, about 60 hours is a safer period for the packing to continue. The scalp drainage, that is the drain through the scalp wound to the dura, if there has been considerable laceration, should be continued for a week. Recumbency with slight elevation of the head should continue until all cerebral symptoms are passed. Light nitrogenous diet should be allowed and as much water as the patient will drink. If stimulation is necessary, I invariably use strychnine, and have found that its stimulating action on the spinal cord never does harm if properly watched and the dose graded. Alcohol is contraindicated,

I think. After three days I usually give bichloride of mercury in full doses, and if the "cerebral irritation," or cerebritis, persists I give ascending doses of potassium iodide with some one of the bromides. The strictest asepsis must be maintained throughout, and the best drainage.

Sequelæ after Complicated Fractures of the Cranium.—A mention is made of a seldom recognized result of severe injury to the cranium, in the *Lancet* of March 6, 1897, in a case published by Drs. Bual and Paulus in the *Correspondenzblatt fur Schweitzer Aerzte*, of a strong young man who had previously had some indications of a tuberculosis of the lung. After a severe cranial injury he developed a well-marked case of tubercular meningitis and died in fourteen days. The diagnosis was confirmed by a post-mortem microscopical examination of the meninges. I have never observed this result, but it seems a very possible occurrence in tubercular subjects. Though I have had a number of cases which lost considerable cerebral cortical tissue, I have never yet observed any persistent or marked lessening of the intellectual faculties in these cases. I have observed a few temporary paralyses, but even in cases when the motor area of the cortex of an extremity on one side seemed entirely implicated the paralysis did not continue. The most important and persistent sequela of complicated fractures of the cranium is *epilepsy*. This occurs more frequently from the adhesion of the cortex to the dura, by means of strong fibrous tissue, than from spiculæ of bone left in the cranium after an operation. The latter source of irritation is so well recognized that surgeons are very careful, as a rule, to prevent it, by sedulously removing all loose and depressed pieces of bone; but it has been only recently that Horsley, Weir and Sachs have called especial attention to the very common result which follows some lacerations of the dura and cortex, which causes a direct suspension, as it were, of the cortex at

the point of injury to the dura and to fibrous membrane which stops up the gap left in the bones after these crushing injuries. The irritation produced by the pulling of this fibrous tissue and the frequent impulses from without, conveyed by this direct connection, seem to be the most prolific causes of the subsequent epileptic attacks. This emphasizes the great importance of always attempting to prevent these adhesions to the cortex. It is for this purpose I have used and recommend the use of gold foil placed *between the lacerated dura and cortex* in operations for complicated fractures implicating the cortex. In one case after the use of the gold foil as indicated, the patient developed epilepsy about two months after leaving the hospital. I operated upon him for the relief of the epilepsy about eighteen months after this. The injury had been about the Rolandic fissure on the left side, and it was a very severe and extensive laceration, with loss of much cortical substance. I found in my second operation that the piece of foil was not large enough to cover in the injured area of the cortex, and that adhesions had formed around the foil on every side. I removed the piece of foil, dissected out the fibrous tissue, carefully separated the adhesions with scissors and introduced a larger piece of gold foil. The patient had no attack while under observation afterwards and I have heard of none since.

The treatment of epilepsy following injuries to the cranium is an operation. This is the one form of epilepsy which the latest authorities declare to be amenable to this treatment. The observations detailed above indicate that not only offending bone, if there be any, but also and especially the fibrous adhesion to the cortex should be carefully dissected away. I would recommend to interpose a piece of gold foil (No. xxx, of the usual dental standard is the thickness I have used) between the dura and cortex (the arachnoid and pia are usually practically destroyed at the point of injury in these cases and need not be

taken into account), and be very careful to see that the piece of foil is broad enough to cover in the whole of the cortical laceration, and extend far enough beyond to prevent the fibrous adhesions which usually occur when this is not done.

COMPOUND COMPLICATED FRACTURES OF THE EXTREMITIES.

First Aid.—Very important, indeed, is it to the sufferer into whose hands he first falls, and that which is done first in the way of treatment. As a rule, the first manifestation to be met in these cases is psychic or nervous shock. This is due either to the terrible mental impression occasioned by the manner of the injury, or to direct injury to a nervous center. In either condition, external heat, or hypodermic administration of full doses of strychnine, is indicated. Alcoholic stimulants do no good, and may do harm.

The next point will be the protection of the wound from further soiling, thus lessening infection. I say this advisedly, as I am convinced it is much more important to lessen or prevent infection first, than to reduce projecting bones, unless this projection itself necessarily increases the danger. Rarely is this the case, however. The bone, if projecting, helps to close up the external wound, and thus reduces the chances of foreign substances entering, and also helps to lessen hemorrhage by its pressure. Besides, and especially, the projecting end of the fractured bone is itself necessarily badly infected, and should not be drawn back within the soft tissues until it has been thoroughly cleaned and disinfected. The especial indication is, therefore, the same great cardinal principle which underlies all good modern surgical work —*asepsis.*

Next prevent hemorrhage, and so prevent the secondary, and may be fatal, so-called "surgical shock." A further argument in favor of not disturbing the relation of the fractured bones until one is prepared

to do so after cleansing and after having at hand the means of controlling hemorrhage, is the fact that the force which caused the displacements frequently closes ruptured vessels by the pressure of the bones, and when they are disturbed, the vessel will open and, perhaps, bleed fatally. Unless a large artery or one of the large vein trunks is certainly severed or lacerated an Esmarch tourniquet is contraindicated, as the pressure of its constriction for any length of time produces such further injury to already badly injured tissues that they will probably slough. Plugging with clean gauze, or several folds of clean muslin or linen cloths, with firm bandaging over the wound, will commonly suffice.

If the hemorrhage is not severe, the next point will be to immobilize the fractured limb. I cannot too strongly deprecate any attempt at reduction of a compound-comminuted, or compound-complicated fracture, at the time one usually renders first aid. That is, along the roadside, in the dust and dirt of a factory, or in the wet smear of a mine. I have seen so many disastrous effects from the soiling and infection thus produced that I would most strenuously urge simply cutting away the clothing, interposing some clean cloths, even a clean board, straw, or hay next the skin, and by improvised splints thoroughly immobilizing the limb without in any way disturbing the axis of the displacement. Such a case ought to be transported to a hospital, or to a house where proper surgical care and final operation and dressing may be done as soon as possible.

First Dressing.—The great essential is *cleanliness.* Place some sterilized gauze over the wound; thoroughly scrub with green soap, shave, and then scrub again an extensive area next to the wound, then the immediate area about the wound. Now the operator should thoroughly scrub and disinfect his hands, and the assistants should all do this. Then douche the wound thoroughly with hot, sterilized

water, and try by prolonged douching to dislodge and remove all foreign substances and blood clots. It is well to use a 1-2000 warm solution of corrosive sublimate, or 1-5000 formalin solution by douching, and by sponging and rubbing with gauze thoroughly clean any projecting bone, and clean out the wound. If, as is frequently the case, the skin wound is too small to see or to properly feel the extent of injury, enlarge the skin wound. Carefully explore the injury with aseptic fingers, and with the eyes if practicable. Remove all loose fragments of bones and badly lacerated soft tissues. Now replace the fragments and bring them into good apposition. Anæsthesia is usually necessary for this. If the fragments are difficult to retain in place by position, fasten them by one of the means to be mentioned later on. Provide for thorough drainage by making a counter-incision at the most dependent point if necessary, and use, whenever practicable, sterilized iodoform gauze for drainage. Next close the wound as far as practicable by sutures. If the skin is in good condition, and the external wound not too irregular and ragged, the suturing may be exact and the wound be thoroughly closed. Silkworm gut properly sterilized or silver wire sutures are best for this. Unless a large vessel has been torn, packing the wound with iodoform gauze will usually suffice to control hemorrhage. The external wound may then have provisional sutures applied, one end of the gauze may be allowed to project through the external wound and be removed after forty-eight hours and the wound finally sutured by tying the sutures firmly. Or the gauze may be drawn out through the drain opening, and be removed through this. Dress the wound with a dry dressing of iodoform gauze immediately over the wound, and thick pads of sterile gauze, cotton, or jute over this and about the limb. Now apply a plaster splint over the whole extremity, while the limb is held carefully in the proper position. If no fever results, and there be no dangerous swell-

ing, do not re-dress for three weeks. A fenestrum, cut in the plaster dressing, opposite the wound, will permit easy dressing without disturbing the position of the wounded extremity.

Operation.—These cases all require some operative assistance as a rule. It is sometimes a very difficult problem to determine what is best to be done. The pressing question usually is—is it necessary to amputate, or can the limb be saved? I have always felt that if there were any possible chance of preserving a useful member, an attempt ought to be made to save the limb. If the chances were a long period of disability (these cases require long periods for restoration of function to the member), and an extremity finally which, though preserved, would be of no practical service to the patient, in cases of manual laborers I question whether the conservative attempt be the wisest determination for the patient. In such cases I think one ought to wait. By careful asepsis prevent extension of the destructive process, and when it is evident there will be no useful recovery, amputation in cases of injury of the *lower extremity* I think ought to be performed. In the upper extremity, if any part of the function of the hand can be preserved, the amputation should be delayed until it may be clearly determined just how much tissue is destroyed, then every increment of a finger or part of the palm possible should be spared; an arm or forearm, though absolutely useless for its own proper functions, is far better than any prothetic apparatus of which I know.

The older works on surgery advised, in cases of serious injury or tearing of a principal vessel or nerve, or "great destruction of the soft tissues," to amputate. My experience has taught me to know that this is bad advice.

It is my practice to individualize every case. In many cases of rupture of one system of bloodvessels and nerves in the forearm and leg, I have been suc-

cessful in saving the member. If both of the principal systems are ruptured, as a rule it is hopeless to attempt to save the extremity, as the interosseous vessels are nearly always torn and the other soft tissues badly lacerated in such cases. In the arm and thigh, if the brachial or femoral arteries are torn high up, the case will usually have almost bled to death before any proper operative procedure can be instituted. These cases usually require amputation if the hemorrhage has been early enough controlled to save the life of the patient. It is more difficult to estimate the indications in cases of considerable loss of bone by comminution, and extensive laceration of the muscles and skin. I have repeatedly saved limbs when the loss of bone did not exceed *five centimeters* of the shaft. These attempts have been successful in every division of the limbs. It must always be borne in mind that compound-comminuted fractures of the bones of the forearm and leg rarely destroy both bones to the same extent. Frequently in the leg an extensive comminution of the tibia occurs, and a simple oblique fracture of the fibula. In removing the shattered part of the principal bone, and in attempting apposition of the proximal and distal ends, it must be remembered to remove a corresponding section from the other bone, else there will be great difficulty in maintaining apposition, and distortion of the member will surely result.

It is of much more importance to have the skin escape extensive contusion and laceration than that the muscles shall have escaped. I cannot recall ever to have saved a limb with a compound-comminuted fracture when as much as one half of the skin of the periphery at the seat of fracture was destroyed. In a number of cases I have been successful when half of the muscular tissue at the seat of the fracture has been destroyed. It is of the greatest importance, therefore, to the salvation of the limb whether the injury to the soft tissues has been produced by direct

or indirect violence. Very rarely will a limb be saved when the compound-comminuted fracture has been produced by a violence which has acted directly on the skin—pressure of a car wheel, for instance, or heavy pieces of metal or stones falling upon the member. Very frequently it will be saved when the lacerations have been produced by the excursions of the fractured ends of the bones, such as result from falls, etc. When both skin and muscles at the seat of fracture are extensively destroyed, conservatism as a rule is useless.

I do not find that a compound-comminuted fracture into a large joint "necessarily requires amputation." The same rules hold good here, as to conservative attempts, as in the shaft, except that much more extensive sections of the bones at the articular ends may be removed than in the shaft. So that an injury of this kind into a joint (barring the loss of the function of the joint) offers better chances of conservatism than elsewhere.

Operative Technique.—Two cardinal points stand foremost in all conservative operative attempts for compound-comminuted fractures. The first is *asepsis* and the second is *thorough drainage.* Without these, favorable cases will do badly, and with them, some most unfavorable, almost hopeless cases, will result in the restoration of good useful limbs. Hence the paramount importance of all measures and precautions to prevent further soiling and infection after these injuries. When the skin is badly contused multiple incisions and drainage by canalization is better than tubes or even gauze, because any extra pressure will almost surely result in necrosis of the skin. As a rule, it is best to drain from the seat of fracture through the muscles at the most dependent part of the injured member; this must usually be accomplished by tubes or gauze. Glass tubes or stiff decalcified bone tubes are not as good as rubber tubes for this, on account of their want of elasticity, which

multiplies or increases pressure. Gauze usually answers perfectly well and is generally preferable. In disinfecting the wound, as a strong solution of sublimate or formalin must be used to be efficient. The ill effects of the chemical on the tissues may be minimized by thorough douching with a normal sterile saline solution at about 110° F. temperature, after the douching with the sublimate or formalin solution.

The third point to be obtained is *good coaptation* and *fixation* after the crushed tissues are removed as far as practicable, and the comminuted fragments of bone taken away. As there nearly always is a loss of bone in these cases, and much laceration of the muscles, it is almost impracticable to maintain apposition of the fragments by any ordinary splinting. For years I have been in the habit of wiring the fragments together with several strands of heavy silver wire, or fastening them together by means of a nickel-plated steel plate of my own devising.

After careful cleansing and disinfection of the limb and the wound, the seat of fracture is carefully explored with aseptic fingers; the external wound is enlarged in order to do this if necessary. The loose fragments of bone are removed, the lacerated muscles trimmed, and then the fragments brought into line. If there is considerable loss of bone, two centimeters or more of the tibia in the leg, or either of the forearm bones, the other is cut down upon, at the seat of fracture, if also fractured, and a section corresponding to the loss of the worse injured bone is removed. (I have never used the ends of a fractured fibula in a crossed position to appose and fill in a gap in a splintered tibia. I think this might be practicable, however, in selected cases.) If the ends of the principal fragments are irregular, and cannot be accurately apposed, they are sawed off in a direction which will assure as little loss of bone as possible, and at the same time good coaptation. Sometimes this

line of section is irregular, so that there is a sort of dovetailing of the fragments when they are brought together; sometimes it is oblique, and sometimes transverse. When the bony surfaces of apposition are irregular or oblique, I find that the plate (which is five centimeters long, five millimeters wide, and two millimeters thick, having six holes or four holes, according as more or less strength is required) is better adapted to hold the fragments firmly in coaptation. The manner of applying it is as follows: The ends of the fracture are brought into coaptation, the plate is laid longitudinally across the line of fracture, and made to rest snugly upon the bone, by chiseling off a little of the rounded surface if necessary, and then a drill (an electric drill is best) is passed through the holes in the plate, and a hole drilled into the bone nearly two centimeters deep, of a diameter corresponding to the hole in the plate (which is about two millimeters). The two end holes are drilled first, and then an ivory peg just large enough and long enough to fill in the hole is driven into these holes, respectively by gentle blows of a mallet. (See figures) These pegs are shouldered, and by a flattened head project two and one-half centimeters from the shoulder. Their flattened surfaces are turned parallel with the axis of the wound in the skin, and they project from the surface of the skin when the wound is closed. Now the ends are fixed; by continued support from below the ends are prevented from sagging, while the other holes are drilled and the ivory pegs driven into place. When the six pegs are inserted the ends of the fractured bone are held firmly in apposition. Now the other bone, if the fracture is in the forearm or leg, is wired or plated as desired, the drains inserted, etc.

If the lines of coaptation are transverse, the silver wire will be best. Usually two cables, of four strands each, are necessary—one passed through drill holes from above downwards, and the other from without inwards, through both ends of the fragments, thus

assuring antero-posterior and lateral support when they are firmly twisted. These cables may be cut short and left permanently in the tissues, the muscles and skin sutured over them, etc. These metal devices for fixation are, when thoroughly aseptic, not only not irritating, but as shown by Drs. Welsh and Halsted, of Johns Hopkins, inhibitory to micrococcal development, and may be safely left in situ as long as necessary. When the plate is used I leave it in place for three or four weeks. It is removed by simply breaking off the ivory pegs at the surface of the bone by grasping the projecting head and twisting it. Remove the head and shoulder of each peg successively, and then by a small opening at one end of the skin wound, first gently rock the plate from side to side; it is loosened and easily removed with a pair of forceps. As I said above, the silver wire may be allowed to remain indefinitely.

I have been using this plate since 1887, and when I first employed it I thought I had been the first to do so. I found, however, that Schede, of Hamburg, had already devised one very similar to mine, and had been using it before mine had been put to use. Schede uses, or did use, a conical steel screw for fastening his plate to the fragments. I use ivory pegs. My work was done in entire ignorance of Schede's device. I have had occasion to show my plate and illustrate its application at several medical meetings, and I believe there are now a number of similar plates in use, and they may easily be had.

After the ends of the fragments are properly fixed, the wound is brought together as closely as practicable in order to assure good drainage, if *no tension is necessary to effect this*. Tissues which have been so badly injured as those about a compound-comminuted fracture usually are, will not stand *stretching*, and this must be carefully avoided, even if the wound must be left partially open. Severed nerves and tendons should be sutured. I prefer fine iron dyed silk

sutures for this. After the wound is closed, and the drains in place, dry the surface and the deep wound by gentle and firm compression by a pad of gauze, and then apply dry sterile dressings. A pretty thick pad of these dressings, laid on uniformly and smoothly, is necessary to absorb the inevitable large discharge of bloody serum, and also to prevent undue compression from the plaster cast. Now, while the limb is carefully held in position by the hands of assistants, or by a proper sling or support of sectional pieces of canvas hung on parallel beams, apply a firm well-fitting plaster splint over the whole dressing, and over the joints next to the fracture, so that the limb may be effectually immobilized and kept so. Unless some special indication should arise the dressings are not disturbed for three weeks. Then a fenestrum is cut in the plaster over the wound, the dressings carefully cut off, the wound inspected, cleansed, the plate removed if the condition of the fragments warrants it, and the wound redressed. Though the wound may remain aseptic and be healing as well as could be hoped, the dressings usually become very malodorous, and on this account it is sometimes well to make a complete change, after three or four weeks, of the whole dressing and cast.

Statistical Argument for Conservative Operations.—Of 194 cases of severe complicated fractures of the extremities of all degrees of severity, from positive comminution of all the tissues to an otherwise uncomplicated compound fracture, 67 cases were operated upon conservatively, that is, for the purpose of removing fragments of bone, uniting fragments, or for drainage, etc., in order to save the extremity. Of these, 55 were cured—that is, limbs restored to full usefulness; 9 were improved—that is, limbs saved, but not fully restored to proper function; 2 required amputation afterwards, and 1 died. One of the cases amputated after the attempt to save the limb, died after the amputation, of septicæmia. This

man had a crushed leg, and refused absolutely to have an amputation at first. It was clearly a case for amputation, as all the soft tissues were badly comminuted, as well as the bones. The conservative operation was done as a forlorn hope. After gangrene set in the man consented to the amputation, but died after the operation of septicæmia. The other case which required amputation was one in which a thrombus occurred in the axillary vessels from the coincident injury to the vessels, and the extremity, which had a very severe compound comminuted fracture of the humerus, had to be amputated on this account. One man died of cerebritis, resulting from a severe head injury received at the same time that his leg was crushed. So that, except the one case of septicæmia (which was the result of the obstinacy and ignorance of the man, and ought not to be classed amongst the conservative attempts), there was no death which could be laid to the conservative operation. Considering that in nearly all these cases there were other injuries, many of them quite severe, and all of the patients recovered after having been transported some distance and handled a great deal, without proper protection in most of the cases, a record of 55 cured and 9 improved—that is, 64 limbs saved out of 67 attempts, and the operations have practically been without fatal result—these statistics are very encouraging to surgeons who have to deal with this class of cases.

This illustrates the external appearance of a severe crush of the lower extremity from a railroad injury.

Estes' plate in position in a case of compound complicated fracture of the leg. The two outer pegs are already driven down, the two inner ones are inserted in the holes ready to be driven down.

INDEX.

	PAGE.
Acetabulum, fractures of the	111
Acromion process, fracture of the	45
Ambulant treatment for fractures of the tibia	163
Anæsthesia in the setting of a fracture	8
Antrum, fractures of the	19
Astragalus, fractures of the	180
Atrophy of supra-scapular muscles after fractures of the tubercles of the humerus	62
Barton's fracture	91
Bavarian splint	83, 135
Carpal bone, fractures of the	96
Catheterization in fractures of the spine	43
Cervical vertebræ, simple fractures of the	34
Clavicle,	48
" Compound comminuted fractures of the	55
" Fracture of the inner end of the	54
" Fracture of the outer end of the	54
" Simple fractures of the	49
Colles' fracture	88
Concussion of the spine	36
Coracoid process, fracture of the	45
Cranium,	12
" basilar fractures of the	193
" compound fractures of the	195
" compound and complicated fractures of the	185
" fissure fractures of the	192
" sequelæ after complicated fractures of the	204
" simple depressed fractures of the	187
Dorsal and lumbar vertebræ, fractures of the	33
Epilepsy following injuries of the cranium	205
Ethmoid bone, fractures of the	15
Extension apparatus for fractures of the shaft of the femur	131
Extremities, compound complicated fractures of the	206
" compound and complicated fractures of the, operation in	209
" compound and complicated fractures of the, conservative operations in	215
Face, fractures of the bones of the	13
Femur,	112
" fractures of the condyles of the	148

INDEX—Continued.

	PAGE.
Femur, fractures of the epiphyseal junction of the...	137
" fractures of the lower end of the.....	137
" fractures of the neck of the.....	112
" fractures of the shaft of the.....	125
" fractures of the trochanters of the.....	125
" oblique fractures of the shaft of the.....	126
" transverse fractures of the shaft of the.....	132
Fibula, fractures of the..... ...	163
First aid in compound and complicated fractures of the extremities.....	206
First dressing in compound complicated fractures of the extremities.....	207
First aid and transportation in fractures.....	5
Fixation plate (Estes).....160, 179,	212
Forearm, fractures of the bones of the.....	78
Fractures, compound and complicated.....	184
Glenoid cavity, fractures of the.....	46
Gold foil, the use of, in lacerations of the dura....200,	205
Hagedorn's splint and Gibson's modification of.....	121
Hall's (Dr. A. L.) treatment of fracture of the greater tuberosity of the humerus.....	61
Hand, fractures of the bones of the.....	96
Humerus, ...	57
" fractures of the condyles of the.....	73
" fractures of the lower end of the.....	69
" fractures of the lower end of the shaft of the.....	70
" fractures of the middle of the shaft of the.	67
" fractures of the surgical neck of.....	62
" fractures of the tubercles of the.....	60
" fractures of the upper end of the shaft of the.....	62
" intracapular fractures of the.....	57
" supra-condyloid or T fractures of the lower end of the.....	76
Inferior maxilla, fractures of the.....	21
Ilium, fractures of the.....	101
Ischium, fractures of the.....	111
Laminectomy,.....	41
Leg, ...	154
" fractures of both bones of the.....	172
" oblique fractures of both bones of the.....	175
" transverse fractures of both bones of the.....	174
Levis segmented shoulder cap.....	66
Lower extremities, fractures of the bones of the.....	101

INDEX—Continued.

	PAGE.
Lungs, lacerations of the	30
Malar bones, fractures of the	16
Malleoli, fractures of the	169
Massage and passive motions after fractures	10
Mediastinum, hemorrhage into the	25
Metacarpal bones, fractures of the	96
Metatarsal bones, fractures of the	183
Musculo-spiral nerve, injury to the	68
Nasal bones, fractures of the	13
Neil's (John) apparatus	178
Olecranon process, fractures of the	78
Os calcis, fractures of the	182
Passive motion after fractures,	10
Patella, fractures of the	142
Patella, mechanical treatment of fractures of the	147
" operative treatment of fractures of the	150
Pelvic bones, fractures of the	101
Perineal section in fractures of the pubes	105
Phalanges of the fingers, fractures of the	99
Phalanges of the toes, fractures of the	184
Pott's fractures of the fibula	166
Pneumo-hemo-thorax	30
Pubis, fractures of the	104
Radius,	84
" fractures of the lower end of the	88
" fractures of the neck of the	85
" fractures of the shaft of the	85
" fractures of the upper extremity of the	84
Ribs,	26
" compound complicated fractures of	29
" simple uncomplicated fractures of	27
Sayre's adhesive strap method in fracture of the clavicle	50
Setting of a fracture	7
Scapula,	44
" fractures of body of the	44
Smith's (Nathan) splint and bandage	127
Spinal column, complicated fractures of the	37
Splints,	9
Sternum, fractures of the	24
Subclavian vessels, injury of the, in fractures of the clavicle	55
Superior maxilla, fractures of the	18
Supra-pubic cystotomy in fractures of the ilium	106
Tarsus, fractures of the bones of the	180

	Page.
Tibia,	155
" oblique fractures of the	157
" transverse fractures of the	155
Transportation in cases of fractures	5
Trophoneurosis of the shoulder	46
Trunk, fractures of the bones of the	24
Ulna,	78
" fractures of the coronoid process of the	81
" fractures of the olecranon process of the	78
" fractures of the shaft of the	81
Velpeau's position and bandage	46
Vertebræ, fractures of the	32
Volkmann's extension splint	117
Vomer, fractures of the	15
Zygomatic arch, fractures of the	17

LANE MEDICAL LIBRARY

To avoid fine, this book should be returned on or before the date last stamped below.

MAY 12 '30
JUN 17 '30

M101 Estes, W.L. Treatment
E79 of fractures.
1900 5686

NAME	DATE DUE
W E Bosley	MAY 12 '30
" "	JUN 17 '30